

SURGICAL REMOVAL OF MESIODENS, A CASE SERIES

Extracción quirúrgica de mesiodens, una serie de casos

José Eduardo Orellana-Centeno,^{1,4} Mauricio Orellana Centeno,^{2,4} Verónica Morales Castillo,³ Javier Leyva Díaz,⁴ Enrique Antonio Martínez Martínez,⁴ Alfonso Acevedo Mascarúa.⁴

Received: November 6, 2025. | Accepted: September 30, 2025. | Published online: May 7, 2026

ABSTRACT

Introduction: Dental anomalies are congenital malformations of the tissues of the tooth that can range from alterations in number, eruption, location, size and shape to structural abnormalities. Among the alterations in number we find the supernumerary tooth, defined as a tooth formed in excessive number.

Material and Methods: Two paediatric patients presented for consultation between June and August 2022 at the dentistry clinic of the Universidad de la Sierra Sur (UN SIS). On clinical and radiographic examination, the presence of a supernumerary tooth located in the palate between the upper central incisors (dental organ 11 and 21) was observed.

Results: The mesiodens type supernumerary teeth were extracted with a surgical technique using a surgical motor and with a favourable operative and postoperative outcome for the patient.

Conclusions: Among the supernumerary teeth, the most common is the mesiodens. Early detection, diagnosis and management is important in order to avoid abnormal development of the patient's dental occlusion and aesthetics.

Keywords: *Tooth abnormalities; Dentition, mixed; Tooth, supernumerary; Tooth extraction; Child; Palate, hard.*

1. Instituto de Investigación Sobre Salud Pública, Licenciatura en Odontología, Miahuatlán de Porfirio Díaz, Oaxaca, México.

2. Facultad de Odontología, San Luis Potosí, S.L.P., México.

3. Instituto Mexicano del Seguro Social, HGZ No. 09, Rioverde, San Luis Potosí, México.

4. Universidad Autónoma Benito Juárez de Oaxaca, Facultad de Odontología, Oaxaca de Juárez, Oaxaca, México.

Corresponding Author:

José Eduardo Orellana Centeno. Universidad de la Sierra Sur Instituto de Investigación Sobre Salud Pública, Guillermo Rojas Mijangos s/n, esq. Av. Universidad C.P. 70800, Miahuatlán de Porfirio Díaz, Oaxaca, México

E-mail: jeorellana@unsis.edu.mx

Orellana-Centeno JE, Orellana Centeno M, Morales Castillo V, Leyva Díaz J, Martínez Martínez EA, Acevedo Mascarúa A. Surgical removal of mesiodens, a case series. *J Oral Res.* 2026; 15(1):4-14. <https://doi.org/10.17126/joralres.2026.002>

RESUMEN

Introducción: Las anomalías dentarias son malformaciones congénitas de los tejidos del diente que pueden presentarse desde alteraciones en número, erupción, localización, tamaño y forma hasta anomalías estructurales. Dentro de las alteraciones en número encontramos al diente supernumerario, se define como aquel diente formado en número excesivo.

Reporte de Caso: Se presentaron dos pacientes pediátricos a consulta en el periodo de junio a agosto del 2022 a la clínica de odontología de la Universidad de la Sierra Sur (UNSI) pacientes pediátricos que a la exploración clínica y radiográfica se observó la presencia de un diente supernumerario ubicados en el paladar, entre los incisivos centrales superiores (órgano dentario 11 y 21).

Resultados: Los dientes supernumerarios tipo mesiodens fueron extraídos con técnica quirúrgica utilizando motor quirúrgico y teniendo un operatorio y postoperatorio favorable para el paciente.

Conclusión: Dentro de los dientes supernumerarios el más común es el mesiodens, es importante se detecte, diagnóstico y manejo temprano esto para evitar un desarrollo anormal de la oclusión dental y estética del paciente.

Palabras clave: *Anomalías dentarias; Dentición mixta; Diente supernumerario; Niño; Extracción dental; Paladar duro.*

INTRODUCTION

Dental anomalies are congenital malformations of the tooth tissues that may involve changes in number, eruption, location, size, or shape, as well as structural abnormalities.¹ Among the numerical anomalies is the supernumerary tooth, or hyperdontia, defined as the presence of an excessive number of teeth or an additional tooth in the normal dentition, whether deciduous or permanent.² Its prevalence has been reported to range from 0.3% to 0.8% in deciduous teeth and from 1.5% to 3.5% in permanent teeth.³ It is more prevalent in Asian populations, whereas in Latin American populations—such as the population examined in this study—the prevalence of mesiodens is 1.7%.⁴ It is also more frequent in men than in women, with a ratio of approximately 2:1.

Additionally, it occurs more commonly in the maxilla and is rare in the mandible.⁵

The etiology of supernumerary teeth is still not clearly defined. Although several theories have been proposed and the condition has been studied extensively, its precise cause remains uncertain. Suggested explanations include dental follicle dichotomy, phylogenetic factors, genetic influences, and the most widely accepted theory, which attributes the anomaly to hyperactivity of the dental lamina during early stages of development. In this context, several molecular signaling pathways involved in dental morphogenesis—such as BMP, FGF, Wnt, and Shh—may be affected. Increased signaling of the latter two pathways in the dental epithelium has been shown to lead to the formation of supernumerary teeth in animal models.^{6,7} Alterations in these genes,

which regulate early developmental processes, could therefore promote the formation of supernumerary teeth.⁸

Most supernumerary teeth are asymptomatic and, therefore, detected only during clinical and radiographic examinations. Radiographic diagnosis can be made using periapical, occlusal, orthopantomographic (panoramic), lateral cephalometric radiographs, or cone-beam computed tomography (CBCT).⁹ Supernumerary teeth are classified according to their number, location, eruption status, and morphology.

- **Number:** Isolated (most frequent) or Multiple (usually associated with a syndrome and may be related to cleidocranial dysplasia, Down syndrome, Fabry–Anderson syndrome, Hallermann–Streiff syndrome, Gardner syndrome, Treacher–Collins syndrome, Rothmund–Thomson syndrome, or cleft lip and palate).¹⁰

- **Location:** Unilateral (found in 76% to 86% of cases, typically in the canine and molar region; where mesiodens have a reported prevalence of 0.15% to 1.9%) or Bilateral (less frequent, occurring in 12% to 23% of cases).¹⁰

- **Eruption:** Classified into three categories: erupted, embedded, and impacted. The most common situation is complete embedding, with only about 25% of supernumerary teeth erupting. Occasionally, these teeth may follow an abnormal eruptive path and adopt an ectopic position, with a risk of eruption into the nasal cavity.¹⁰

- **Morphology:** Four forms have been described: conical (peg-shaped, most common), tuberculate (barrel-shaped), supplemental (similar in shape to adjacent teeth), and rudimentary-dysmorphic (small, often conical shape).¹⁰

Among supernumerary teeth, the most common type is the mesiodens. It is typically located between the maxillary central incisors and may be single, unilateral or bilateral, erupted or impacted, and oriented vertically, horizontally, or in an inverted position. According to Shafer *et al.*,¹¹ mesiodens account for more than 50% of all supernumerary teeth.

Mesiodens can present in these different forms:

a) Rudimentary (the most common, typically conical in shape); b) Eumorphic (resembling the shape of normal teeth); and c) Heteromorphic (with atypical morphology).¹²

A thorough intraoral examination is essential, as a protuberance may occasionally be observed on the buccal or palatal mucosa.¹³

The radiographs commonly used to determine the palatal or buccal position of a mesiodens include occlusal radiographs and periapical radiographs taken with different horizontal angulations, following Clark's technique, which applies the principle of parallax or the buccal object rule.¹⁴

Complications associated with the presence of a mesiodens include:

a) Displacement, rotation, or interference with normal tooth eruption; b) Delayed eruption of the permanent maxillary central incisors; c) Root resorption or abnormal root formation; and d) Effects on adjacent vital structures, such as perforation of the nasopalatine canal or nasal floor, or the development of cysts.¹⁵

The exact criteria for planning the treatment of mesiodens remain unclear. The decision is made by the dentist based on the patient's age and the characteristics of the mesiodens.¹⁶ The aim of this study is to describe the surgical removal of mesiodens in a series of cases.

CASE REPORT

Clinical Case 01

An asymptomatic patient attended the dental clinic of the Universidad de la Sierra Sur (UN SIS) on June 21, 2022. The patient was an 8-year-old male attending for a routine dental examination. A clinical history was obtained, and panoramic, periapical, and occlusal radiographs were taken. He had no relevant pathological or non-pathological history. Following the clinical and radiographic evaluation, he was diagnosed with crowding in the anterior segment of the maxilla and a dental anomaly—specifically, a supernumerary tooth of the mesiodens type. His mother was informed of the

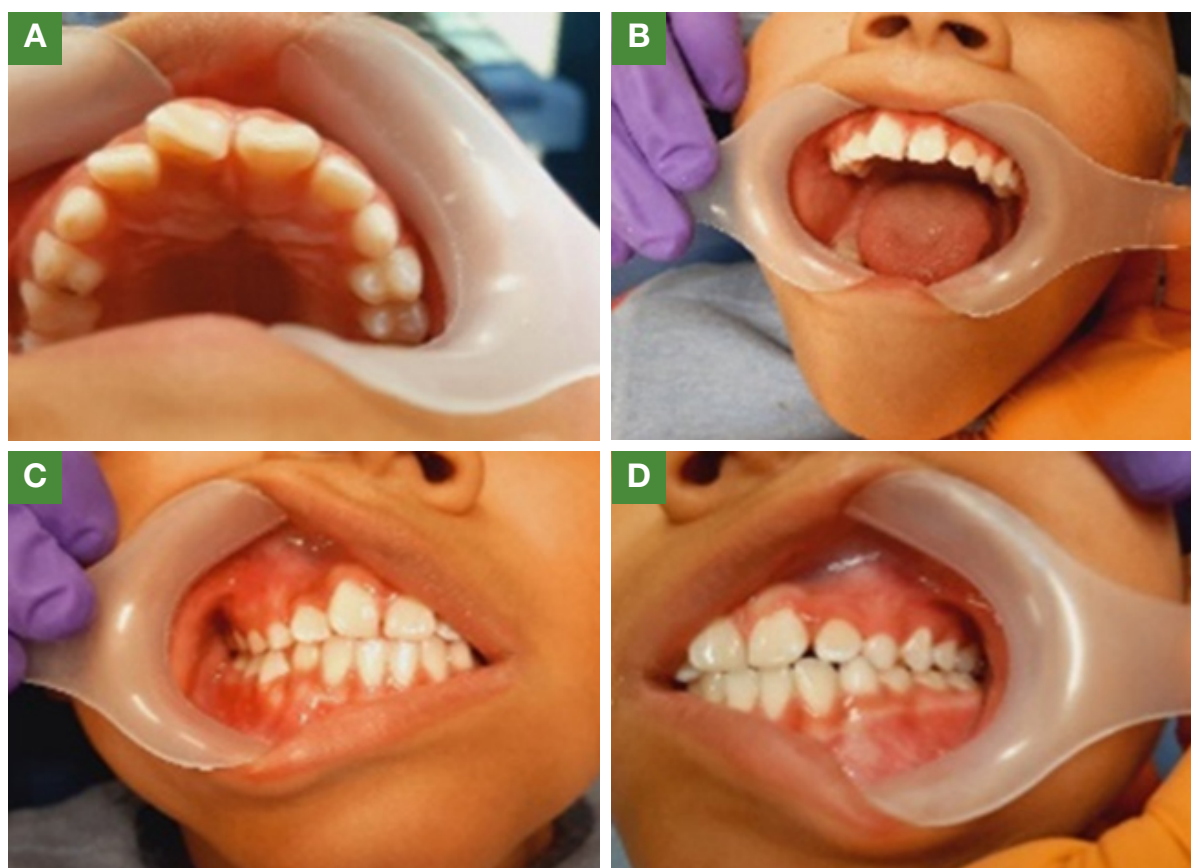diagnosis and the proposed treatment plan, and she accepted and signed the informed consent form.

The supernumerary tooth was located on the palatal side between the upper central incisors (teeth 11 and 21), causing an alteration in their position. It presented the following characteristics: isolated, single, rudimentary–dysmorphic in shape and impacted, (Figure 1).

Auxiliary examinations were performed using periapical and occlusal radiographs, which confirmed the diagnosis. (Figure 2) Following diagnosis and authorization from the patient’s mother, the oral cavity and the area to be treated were cleaned and disinfected. Topical anesthesia was applied, and local anesthesia was

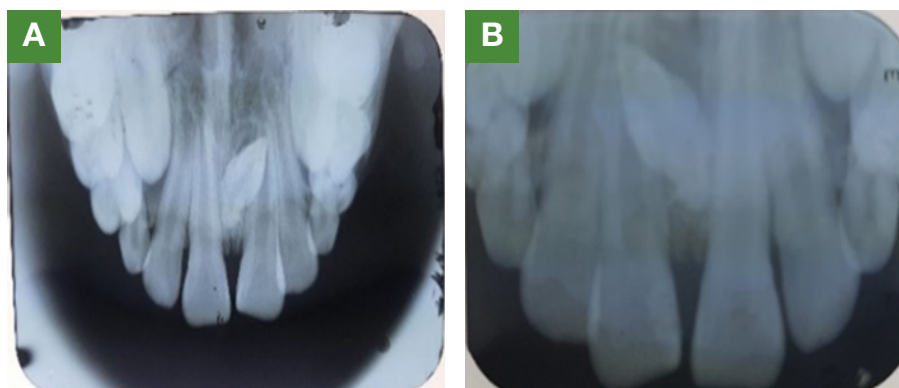
Figure 1

Extraoral images



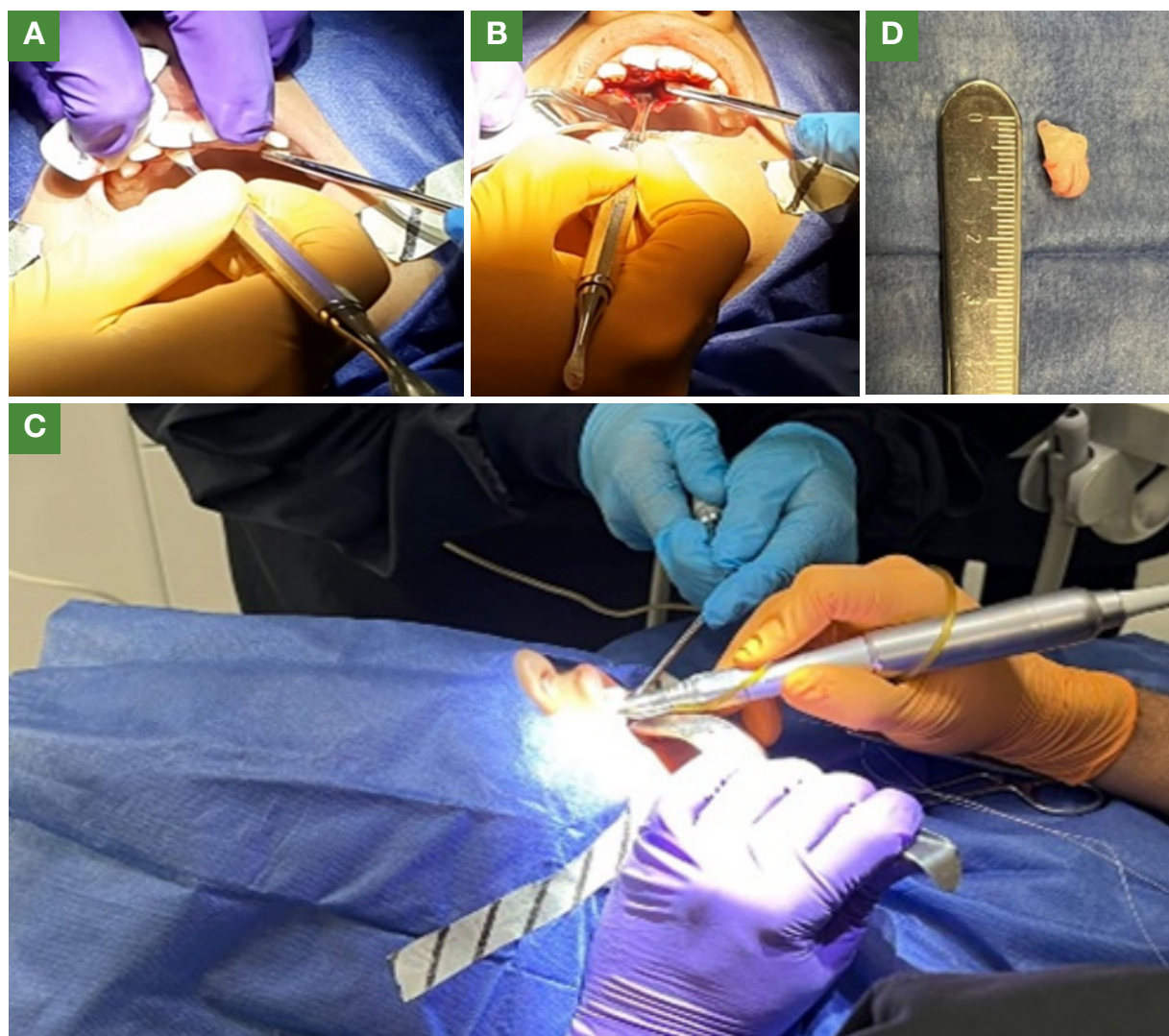
A: Occlusal view of upper teeth. **B:** View of oral cavity with mouth open. **C:** Right lateral view. **D:** Left lateral view.

Figure 2
Radiographs



A: Occlusal radiograph of the mesiodens. **B:** Periapical radiograph of the mesiodens.

Figure 3
Surgical extraction procedure



A: Syndesmotomy. **B:** Flap elevation. **C:** Osteotomy to release impacted mesiodens. **D:** Mesiodens extracted.

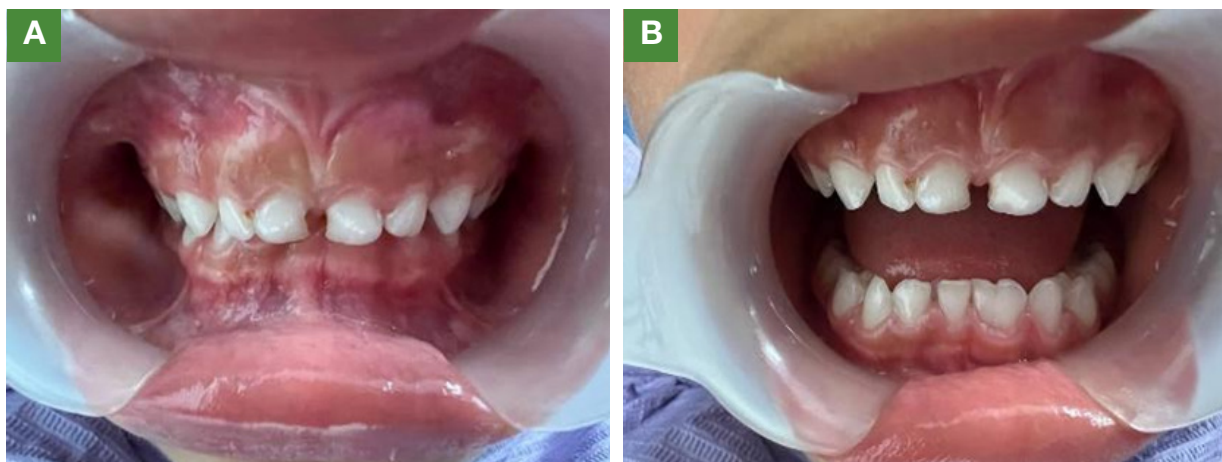administered by infiltration from the upper right canine (53) to the upper left canine (63), as well as palatally at the incisive papilla, using two cartridges of FD 2% lidocaine HCl with epinephrine (FD Zeyco, Laboratorio Zeyco S.A. de C.V., Zapopan, Jalisco, Mexico). A sulcular incision was then made from the upper right canine to the upper left canine using a No. 3 scalpel handle and a No. 12 blade, creating an enveloping flap. Using a curette, the mucoperiosteal flap was raised, exposing part of the mesiodens. An osteotomy was performed to fully expose the tooth. Careful luxation was carried out to avoid damage to the

surrounding tissues and to facilitate extraction, using constant irrigation with saline solution. The supernumerary tooth was then extracted (Figure 3).

Finally, the area was sutured with a resorbable suture (Vicryl 4-0). Postoperative instructions were provided, including an antibiotic (amoxicillin-clavulanic acid 500 mg tablets for 7 days) and an analgesic (ibuprofen 400 mg tablets for 3 days). The patient was advised to drink plenty of water and rest during the first few days. Postoperative appointments were scheduled to clinically monitor progress.

Figure 4

Extraoral images



A: Frontal view showing deep bite. **B:** Frontal view with mouth opening showing low implantation of the upper frenulum and geminated tooth (71,72).

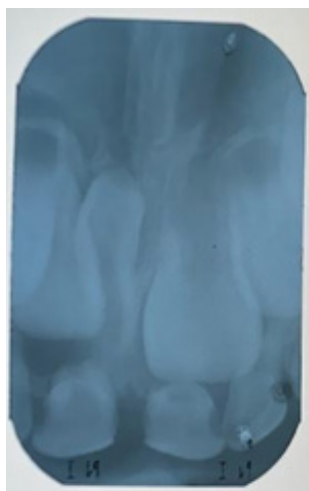Clinical Case 02

A 6-year-old female patient attended a check-up at the dental clinic of the Universidad de la Sierra Sur (UNSI) on August 11, 2022. A medical history was taken, and panoramic, periapical, and occlusal radiographs were obtained. She presented with no relevant medical

or non-medical history. Following the clinical and radiographic examination, she was diagnosed with a deep bite and two dental anomalies: a supernumerary mesiodens in the anterior maxillary segment and two geminated teeth (71 and 72). Her mother was informed of the diagnosis and treatment plan, and

Figure 5

Periapical radiograph of the mesiodens




she accepted and signed the informed consent form. A clinical examination of the patient was performed (Figure 4).

The supernumerary tooth was located on the palate, between the upper central incisors (teeth 11 and 21), causing an alteration in the position of these teeth. It displayed the following characteristics: isolated, single, rudimentary, dysmorphic, and impacted. A fused tooth (teeth 71 and 72) was also observed (Figure 5).

Following diagnosis and with the mother's consent, the oral cavity and treatment area were prepared using aseptic and

Figure 6

Documentation of the surgical procedure including the equipment used for the extraction, and the biological material removed.



A: Equipment used to perform the extraction of the mesiodens. **B:** Geminated tooth extracted. **C:** Mesiodens extracted.

antiseptic techniques. Topical anesthesia was applied, followed by infiltration anesthesia from the upper right canine (53) to the upper left canine (63), as well as palatally at the incisive papilla, using two cartridges of 2% lidocaine FD with HCl and epinephrine (FD Zeyco, Laboratorio Zeyco S.A. de C.V., Zapopan, Jalisco, Mexico). A sulcular incision was then made from the upper right canine to the upper left canine using a No.

3 scalpel handle and a No. 12 scalpel blade, creating an enveloping flap. The mucoperiosteal flap was elevated with a curette, enabling visualization of a portion of the mesiodens. An osteotomy was performed with a Surgic Ap surgical motor (NSK Nippon Seiko KK, Tokyo, Japan) to fully expose the tooth. Careful luxation was carried out under constant saline irrigation to avoid damage to the surrounding tissues and

facilitate extraction. The supernumerary tooth was then extracted, (Figure 6). The area was subsequently sutured with resorbable sutures (Vicryl 4-0). Anesthesia for the extraction of the fused tooth was administered using the lower dental technique. After applying topical anesthesia, one cartridge of 2% lidocaine FD with HCl and epinephrine (FD Zeyco, Laboratorio Zeyco S.A. de C.V., Zapopan, Jalisco, Mexico) was used. Luxation and avulsion of the fused tooth were performed with 151SK forceps. Once the tooth was removed, the site was sutured with resorbable sutures (Vicryl 4-0). Postoperative instructions were provided, including an antibiotic (amoxicillin with clavulanic acid, 500 mg tablets for 7 days) and an analgesic (ibuprofen, 400 mg tablets for 3 days). The patient was advised to drink plenty of water and rest during the first few days. Postoperative appointments were scheduled to clinically monitor treatment progress (Figure 6).

DISCUSSION

Two cases of patients with mesiodens supernumerary teeth were presented, both involving individuals without associated syndromes or relevant medical histories. In both cases, the mesiodens were located in the anterior segment of the maxilla and had gone undetected. The lack of symptoms meant that neither condition prompted a consultation, and both were discovered incidentally during routine examinations. In the first case, the patient presented with mixed dentition, and the mesiodens was extracted due to its potential for occlusal complications. In the second case, the pa-

tient exhibited predominantly deciduous dentition and an additional dental anomaly: a geminated tooth in the mandible. Neither patient presented with any syndrome associated with the oral pathologies observed. The etiology of mesiodens remains unknown. Several theories have been proposed, including atavism (evolutionary regression leading to three central incisors), germ dichotomy (division of the dental follicle into two), genetic factors (autosomal dominant or recessive inheritance, or associations with the X chromosome), alterations in organogenesis, hyperactivity of the dental lamina, and associations with certain syndromes (such as Down syndrome, Gardner syndrome, and cleidocranial dysplasia), as well as systemic conditions (such as cleft lip and palate). A combination of environmental and genetic factors has also been suggested.¹⁷ Dental diagnosis should be based on a thorough clinical and radiographic examination to detect swelling, malpositioned teeth, crowding, spacing, or chronological alterations in the eruption process.¹⁸ A 3D digital positioning guide can provide clinicians with detailed patient information during the surgical procedure. This information allows for appropriate assessment of risks and planning of the surgical approach, including incision design, surgical fenestration, and the angle and depth of the operation. In their study, Aji *et al.*,¹⁹ developed a surgical plan using 3D digital templates to accurately extract impacted supernumerary teeth with minimally invasive techniques, even in complex locations such as the lingual side of the mandible. Management of supernumerary teeth depends on their type and location, as well as their functional, aesthetic, and other impacts on the deciduous or permanent dentition. Immediate extraction is indicated in cases involving delayed or inhibited

eruption, displacement of adjacent teeth, interference with orthodontic appliances, the presence of a pathological condition, or spontaneous eruption of the supernumerary tooth.²⁰

According to Stafne *et al.*,²¹ 6% of impacted supernumerary teeth are associated with dentigerous cysts, which can cause bone destruction as they continue to grow, become infected, undergo histological changes, and, in exceptional cases, become malignant. In the case of mesiodens supernumerary teeth, two extraction approaches are described: (a) Early extraction, performed before the formation of the permanent incisor roots, and (b) Late extraction, carried out after root formation. Some authors recommend performing the extraction during

early mixed dentition, corresponding to the first type. This report presents one case of each approach. Although the surgical procedure itself does not differ, it is important to note that extraction at an earlier stage may reduce the need for future orthodontic treatment.²²

CONCLUSIONS

These cases demonstrate that mesiodens in children may remain asymptomatic and be detected only during routine examinations. Early identification is important to prevent potential occlusal complications. In both cases, surgical extraction of the mesiodens resulted in a successful resolution without complications.

REFERENCES

1. Azaura D, Flores C, Rivas R. Conducta ortodóntica frente a la presencia de mesiodens: reporte de caso. *Odontol. Sanmarquina* 2020; 23(2): 173-
[doi:10.15381/os.v23i2.17763](https://doi.org/10.15381/os.v23i2.17763)
2. Barham M, Okada S, Hisatomi M, Khasawneh A, Tekiki N, Takeshita Y, Kawazu T, Fujita M, Yanagi Y, Asami J. Influence of mesiodens on adjacent teeth and the timing of its safe removal. *Imaging Sci Dent.* 2022;52(1):67-74. [doi: 10.5624/isd.20210218](https://doi.org/10.5624/isd.20210218). Epub 2022 Jan 13. PMID: 35387109; PMID: PMC8967489.
3. Finkelstein T, Shapira Y, Pavlidi AM, Schonberger S, Blumer S, Sarne O, Shpack N. Prevalence and Characteristics of Supernumerary Teeth in Israeli Orthodontic Patients. *J Clin Pediatr Dent.* 2019;43(4):244-251. [doi: 10.17796/1053-4625-43.4.4](https://doi.org/10.17796/1053-4625-43.4.4). Epub 2019 May 16. PMID: 31094630.
4. Tetay-Salgado S, Arriola-Guillén LE, Ruíz-Mora GA, Aliaga-Del Castillo A, Rodríguez-Cárdenas YA. Prevalence of impacted teeth and supernumerary teeth by radiographic evaluation in three Latin American countries: A cross-sectional study. *J Clin Exp Dent.* 2021 Apr 1;13(4):e363-e368. [doi: 10.4317/jced.57757](https://doi.org/10.4317/jced.57757). PMID: 33841735; PMID: PMC8020316.
5. Cammarata-Scalisi F, Avendaño A, Callea M. Main genetic entities associated with supernumerary teeth. *Arch Argent Pediatr.* 2018;116(6):437-444. English, Spanish. [doi: 10.5546/aap.2018.eng.437](https://doi.org/10.5546/aap.2018.eng.437). PMID: 30457727.
6. Tetay-Salgado S, Arriola-Guillén LE, Ruíz-Mora GA, Aliaga-Del Castillo A, Rodríguez-Cárdenas YA. Prevalence of impacted teeth and supernumerary teeth by radiographic evaluation in three Latin American countries: A cross-sectional study. *J Clin Exp Dent.* 2021 Apr 1;13(4):e363-e368. [doi: 10.4317/jced.57757](https://doi.org/10.4317/jced.57757). PMID: 33841735; PMID: PMC8020316.

7. Lu X, Yu F, Liu J, Cai W, Zhao Y, Zhao S, Liu S. The epidemiology of supernumerary teeth and the associated molecular mechanism. *Organogenesis.* 2017; 13(3): 71-82. doi: 10.1080/15476278.2017.1332554.
8. Fuentes R, Álvarez G, Garay I, Arias A. & Dias FJ. Dientes supernumerarios suplementarios en un paciente adulto parcialmente dentado: Reporte de caso. *Int. J. Morphol.* 2018; 36(2): 478-482. doi:10.4067/S0717-95022018000200478
9. Lévano S, Perea M. Múltiples dientes supernumerarios en un paciente pediátrico no sindrómico: una condición rara. *Rev Estomatol Herediana.* 2020; 30(2): 120-125. doi:10.20453/reh.v30i2.3764
10. Matías A. Mesiodens. Reporte y seguimiento de un caso. *Odontol Pediatr* 2018; 17(2): 79 - 84.
11. Navas Aparicio M. Prevalencia de dientes supernumerarios en pacientes con labio y paladar hendido mediante el análisis de ortopantomografía. *Revista cirugía oral maxilofacial.* 2017; 39(3): 171-178. doi:10.1016/j.maxilo.2016.03.004.
12. Pulido Valladares Y, Gounelas Amat S, Rezk Díaz A. Aparato tipo Hawley con modificaciones en incisivo central retenido por supernumerarios. *Rev. Ciencias Médicas* 2021; 21(2): e4774.
13. Verás MA, Scougall RJ, Robles NL, Lucas SE, Casanova AJ, Casonava JF, Medina CE. Mesiodens: Diagnóstico, aspectos clínicos, radiográficos y tratamiento. *Revisión bibliográfica. Avances en Biomedicina* 2018; 7(3): 166-173.
14. Şen Yavuz B, Sezgin BI, Pekel B, Korkut B, Menteş A. Management options and long-term follow-ups for permanent double incisors: six to eleven-year case reports. *BMC Oral Health.* 2024;24(1):225. doi: 10.1186/s12903-024-04000-7. PMID: 38350932; PMCID: PMC10863289.
15. Stierling M.C, Ramírez D.V., Lazo S.R. Múltiples dientes supernumerarios en paciente pediátrico no sindrómico, una revisión de la literatura y presentación de caso clínico. *Int. J. Odontostomat.* 2023; 17(3): 255-263. doi: 10.4067/S0718-381X2023000300255
16. Fernández M. J, Vélez León E. M, Reinoso Quezada S. J. Intervención temprana de dientes supernumerarios en dentición primaria: Reporte y seguimiento de caso clínico. *Rev. Odontoped. Latinoam.* 2023; 13: e-224555. doi:10.47990/alop.v13i.555.
17. Aparcana Quijandría P.M. J, Huamani Echaccaya J. L. Supernumerarios múltiples no sindrómicos en dentición permanente. Reporte de caso. *Rev. Estomatol. Herediana* 2020; 30(4): 302-307. doi:10.20453/reh.v30i4.3884.
18. Liu M, Yang X, Lv K, Li Z. Minimally-invasive alternative to the extraction of deeply-impacted supernumerary teeth using a computer designed surgical template. *British Journal of Oral and Maxillofacial Surgery.* 2019; 57: 285–287. doi: 10.1016/j.bjoms.2019.01.013.
19. Aji Y, Guan R, Zhang X.L, Zhang J.H, Ma J.P. Minimally invasive surgical removal of bilateral impacted mandibular supernumerary teeth using 3D surgical guide template: a case report. *J Clin Pediatr Dent* 2024; 48(2): 204-8. doi: 10.22514/jocpd.2024.049
20. Moradinejad M, Hashemi Ashtiani A, Rakhshan V. Multiple nonsyndromic unerupted supernumerary teeth: a report of a rare case. *Case Rep. Dent.* 2022; 4063856. doi: 10.1155/2022/4063856.
21. Jain A, Taneja S. Bilateral presentation of different supernumerary teeth in nonsyndromic patients: case reports. *Gen Dent.* 2020; 68(2): 39-42.
22. Tworkowski K., Gasowska E., Baryla D., Gabiec K. Supernumerary teeth – literature review. *Journal of Pre-Clinical and Clinical Research.* 2020;14(1):18–21. doi: 10.26444/jpccr/119037.

CONFLICT OF INTERESTS

The authors declare no conflict of interest.

ETHICS APPROVAL

It is not necessary.

FUNDING

Does not have a source of financing.

AUTHORS' CONTRIBUTIONS

José Eduardo Orellana-Centeno: Conceptualization; Data curation; Formal analysis; Investigation; Methodology; Project management; Software; Validation; Visualization; Drafting; Revision and editing.

Mauricio Orellana Centeno: Conceptualization; Investigation; Validation; Revision and editing.

Verónica Morales Castillo: Conceptualization; Data curation; Investigation; Validation; Drafting; Revision and editing.

Javier Leyva Díaz: Conceptualization; Investigation; Validation; Revision and editing.

Enrique Martínez Martínez: Conceptualization; Investigation; Validation; Revision and editing.


Alfonso Acevedo Mascarúa: Conceptualization; Investigation; Validation; Revision and editing.

ACKNOWLEDGEMENTS


None.

ORCID


José Eduardo Orellana-Centeno

 0000-0002-9518-7319


Mauricio Orellana Centeno

 0000-0003-3374-9766


Verónica Morales Castillo

 0009-0005-4488-421X


Javier Leyva Díaz

 0009-0002-8541-8176

Enrique Antonio Martínez Martínez

 No aplica

Alfonso Acevedo Mascarúa

 No aplica

PUBLISHER'S NOTE

All statements expressed in this article are those of the authors alone and do not necessarily represent those of the publisher, editors, and reviewers.

COPYRIGHT

This is an open-access article distributed under the terms of the Creative Commons Attribution License (CC BY 4.0). The use, distribution or reproduction in other forums is permitted, provided the original author(s) and the copyright owner(s) are credited and that the original publication in this journal is cited, in accordance with accepted academic practice. No use, distribution or reproduction is permitted which does not comply with these terms. ©2026.



PEER REVIEW

This manuscript was evaluated by the editors of the journal and reviewed by at least two peers in a double-blind process.

PLAGIARISM SOFTWARE

This manuscript was analyzed Compilatio plagiarism detector software. Analysis report of document ID. 5a012765787eb68ec0fcc2652f5cff525b311e48

ISSN Print 0719-2460 - ISSN Online 0719-2479

<https://joralres.com/index.php/JOralRes>