

REGENERATION OF A LARGE BONY LESION WITH ADVANCED-PLATELET RICH FIBRIN : A CASE REPORT

Regeneración de una lesión ósea de gran tamaño con fibrina rica en plaquetas: Reporte de Caso

Ravi Gupta,¹ Sagrika Shukla.²

1. Department of Conservative Dentistry and Endodontics, Manipal University College Malaysia (MUCM), Jalan Batu Hampar, Bukit Baru, 75150 Melaka, Malaysia.

2. Shree Guru Gobind Singh Tricentenary University, dental college, Gurgaon, India.

ABSTRACT

Introduction: This case report analyzes the regeneration potential of advanced-platelet rich fibrin (A-PRF) in large bony lesions. Advanced-platelet rich fibrin provides various growth factors which aids in faster healing.

Materials and Methods: Patient presented with peri-apical radiolucency. CBCT showed bony radiolucency in teeth 31, 32, 41, 42. A full mouth mucoperiosteal flap was raised and a cyst lining was enucleated. Apicoectomy was done with respect to 31, 32, 41, 42 along with and retrograde with a preparation of APRF clots were placed in the bony cavity.

Results: Post-op CBCT at 6 months showed a significant difference in size and bone density of the lesion.

Conclusions: Advanced-platelet rich fibrin has shown promising results in reducing the size of bony defect and periapical lesion in this case.

Keywords: *Cysts; Apicoectomy; Endodoncia Regenerativa; Platelet-Rich Fibrin; Regeneration; Cone-Beam Computed Tomography.*

RESUMEN

Introducción: Este caso clínico demuestra el potencial de regeneración de la fibrina rica en plaquetas avanzada (A-PRF) en lesiones óseas de gran tamaño. La fibrina rica en plaquetas avanzada proporciona varios factores de crecimiento que ayudan a una curación más rápida.

Materiales y Métodos: El paciente se presentó con radiolucencia periapical. Tomografía computarizada de haz cónico mostró radiolucencia ósea en los dientes 31, 32, 41, 42. Se levantó un colgajo mucoperiosteal de boca completa y se enucleó el revestimiento del quiste. Se realizó apicectomía con respecto a 31, 32, 41, 42, y se colocó una preparación de APRF se colocaron coágulos en la cavidad ósea.

Resultados: La tomografía computarizada de haz cónico postoperatorio a los 6 meses mostró una diferencia significativa en el tamaño y la densidad ósea de la lesión.

Conclusión: La fibrina rica en plaquetas avanzada ha mostrado resultados prometedores en la reducción del tamaño del defecto óseo y la lesión periapical en este caso.

Palabras Clave: *Quistes; Apicectomía; Endodoncia regenerativa; Fibrina rica en plaquetas; Regeneración; Tomografía computarizada de haz cónico.*

CORRESPONDING AUTHOR: Ravi Gupta.
Departamento de Odontología Conservadora y Endodoncia, Manipal University College Malaysia (MUCM), Jalan Batu Hampar, Bukit Baru, 75150 Melaka, Malasia. E-mail: vigupta641@gmail.com

CITE AS: Gupta R & Shukla S. Regeneration of a large bony lesion with advanced-platelet rich fibrin: A case report. J Oral Res. 2023; 12(1): 100-107.
doi:10.17126/joralres.2023.009

Received: September 23, 2022
Accepted: January 02, 2023
Published online: May 03, 2023
ISSN Print 0719-2460
ISSN Online 0719-2479

INTRODUCTION

Endodontic infections or periodontal infections, if left untreated, can reach the alveolar bone, resorbing the underlying bone and leading to multiple problems such as bone loss and tooth mobility, ultimately leading to the extraction of the tooth involved. This further leads to multiple treatments, multiple dental office visits, which are time consumption and represent a financial burden on the patient. Thus, the treatment of the most common diseases of dentistry becomes paramount not only to control and reduce the aforementioned problems but also to stop the spread of infection elsewhere in the body. The human body has an excellent ability to heal and regenerate only when the lesions or pathology has been removed.

Tissues heal due to growth factors, including those secreted by platelets,¹ and we currently are able to extract these platelets so that a boost of concentrated growth factors can be applied at the site where healing is required.¹ Based on this concept, platelet rich plasma (PRP) was firstly harvested and utilized, leading subsequently to the use of injectable platelet rich fibrin (iPRF) and advanced-platelet rich fibrin (APRF), both developed by Choukron *et al.*,² and based on the low-speed centrifugation concept (LSCC).

The advantage of using iPRF and APRF is that along with growth factors, these biomaterials also provide stem cells.² These biomaterials are injectable or can be converted into a clot or a membrane, thus

have a wide range of applications. In this case report a form of APRF was used to enhance healing in a periapical bony lesion after its complete enucleation.

CASE REPORT

A 23-year-old female patient visited the dental office with a chief complaint of pain in the lower front teeth region which was associated with swelling. She gave a history of undergoing root canal treatment of lower anterior teeth two years previously and noticed gradual discoloration of said teeth and pus discharge, causing a swelling to grow in size. Once the pus discharges the swelling subsides and reoccurs after a few days. No relevant medical history was given by the patient.

Intraoral examination revealed a soft tissue swelling in the vestibular area extending from lower canine to canine (Figure 1). An intraoral periapical radiograph revealed a large well defined periapical radiolucency with sclerotic border in relation to the apices of 31, 32, 41, 42. Preoperative CBCT (Veraviewepocs, J. Morita, Japan) was obtained in order to assess the spatial configuration of the lesion.³ A 3D reconstructed section of mandible anterior teeth by using CS 3D Imaging software showed a well-defined radiolucency with a sclerotic border at the apex of 31, 32, 41 and 42 measuring approximately 4 mm in dimension with partial loss of the buccal-cortical plate (Figure 2A). Root canal treatment of the four teeth involved was redone under rubber dam isolation (31, 32, 41, 42) and the access to the cavity was sealed with glass ionomer.

Routine blood investigations were carried out and the patient was prescribed prophylactic antibiotics one day prior to surgery.

Patient consent was obtained prior to the surgical procedure. A surgical procedure was done, where after anesthetizing the area by giving IANB nerve block, two vertical releasing incisions were placed on both the sides of lower canines and a full thickness mucoperiosteal flap was elevated. The cyst lining was noticed and the cyst was enucleated (Figure 2B). Apicoectomy was done with respect to 31, 32, 41, 42 and retrograde preparation of the same was done using a ultrasonic retro preparation tips (Pro surgical endo tips, Dentsply). The retrograde filling was done using Mineral trioxide aggregate (MTA) (ProRoot™MTA; Dentsply, USA).

Forty milliliters of blood were collected from the right cubital vein and centrifuged at 1300 rpm for eight minutes to obtain APRF

(Duoqauto, Nice, France) (Figure 3A), according to Choukron *et al.*,² which was then used to fill the bony defect (Figure 3B).

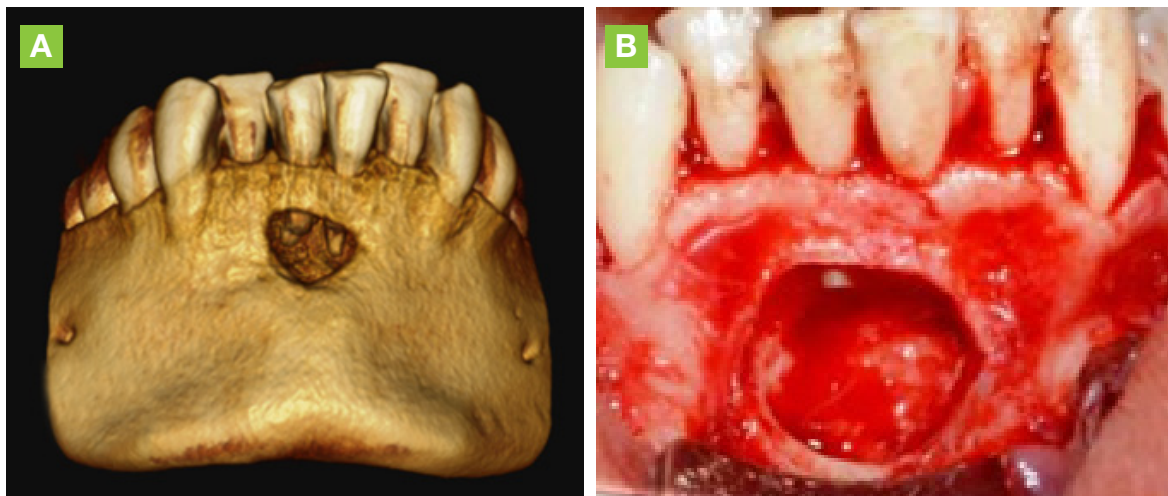
The flap was repositioned and sutured using 3-0 Vicryl suture. Immediate post-operative intraoral periapical radiograph revealed satisfactory obturation with retro-grade filling intact. The histopathology report confirmed the diagnosis of an infected radicular cyst. Post-operative instructions were given to the patient and the patient was prescribed antibiotics (amoxicillin 500mg thrice a day) and analgesics (paracetamol 500mg thrice a day) for 5 days, and the patient was discharged.

The patient was recalled at intervals of 7 days, 3 months and 6 months. Samples of cystic lining and tissue were sent for histopathological analysis, which confirmed the diagnosis of radicular cyst.

Figure 1: Soft tissue swelling in the vestibular area extending from lower canine to canine.

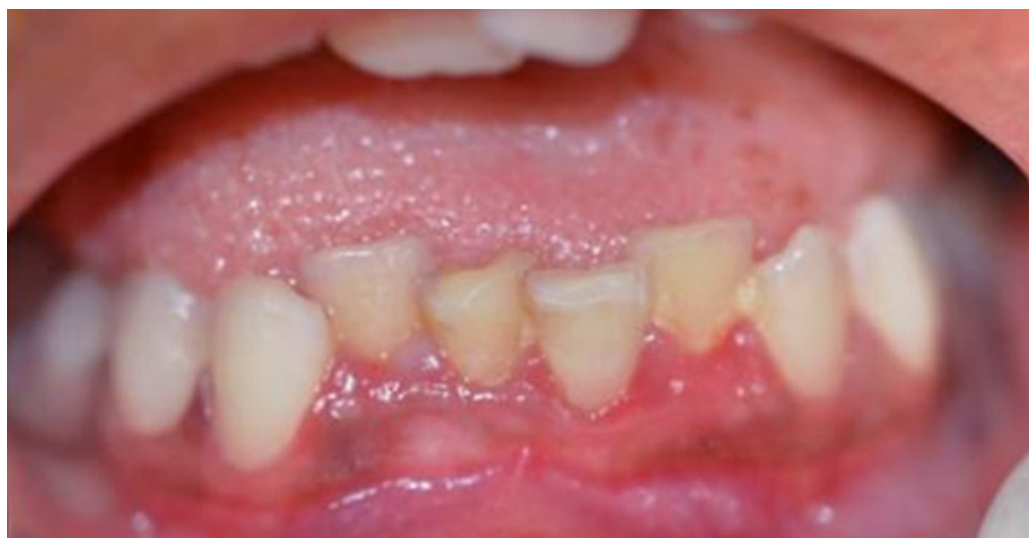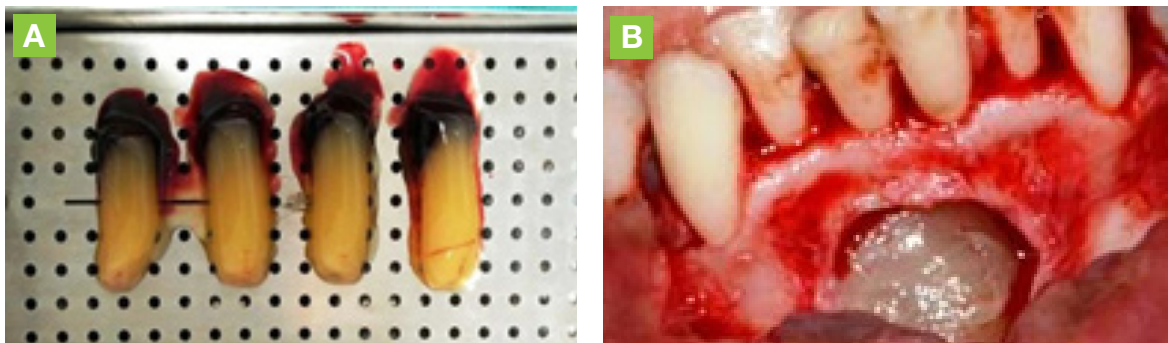


Figure 2: 3D reconstruction of the anterior teeth of the mandible and enucleation of the cyst.



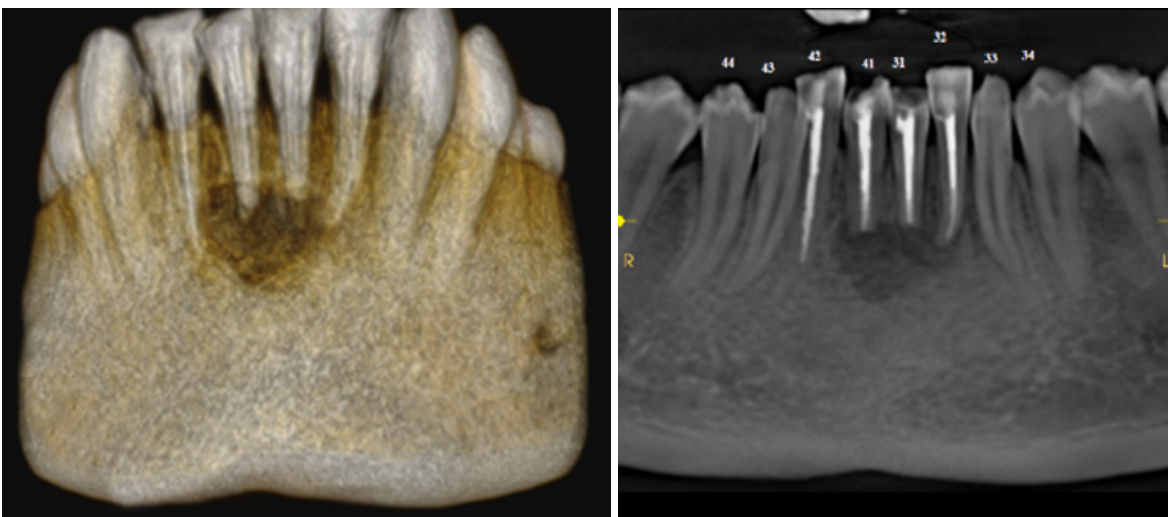
A: 3D reconstructed section of mandible, anterior teeth showed a well-defined radiolucency with a sclerotic border at the apex of 31, 32, 41 and 42. **B:** Cyst was enucleated and root resection was done.

Figure 3: Advanced-platelet rich fibrin application.



A: Advanced-platelet rich fibrin was extracted. **B:** Advanced-platelet rich fibrin was used to fill the bony defect.

Figure 4: Six months after surgery imaging shows a reduction in the size of periapical defect, demonstrating healing of the cystic lesion.



RESULTS

Immediately postoperatively the patient did not report any pain or severe discomfort. Mild discomfort was noted, which is acceptable in cases of oral surgeries. There was no pain or notable swelling at the surgical site. Oral hygiene instructions were reinforced. At suture removal, healing was satisfactory and the surgical site has been kept clean by the patient.

Six months post surgery CBCT showed a reduction in the size of periapical defect demonstrating healing of the cystic lesion, even though no bone graft was used to fill the bone defect (Figure 4).

DISCUSSION

As aforementioned, once the infection crosses root canals and reaches the alveolar bone, it results in resorption of the bone and the lesion enlarges in size causing teeth mobility and delay in bone healing, even after root canal treatment. In such cases it is always better to remove all the pathology from the canals as well as the bony lesion as well.

Apicoectomy is the preferred choice of treatment and is very commonly performed by the dental surgeon. It has the advantage of removing all the microbial infection from the bony lesion and the root canals, decreasing the chances of reinfection almost to nil. To enhance bone healing at such sites, bone graft or a composite of growth factors and bone graft can be used, however, authors in this case used clots of APRF to enhance bone healing.

Briefly, APRF is obtained by LSCC² where the concentration of growth factors is maximized by centrifuging blood just enough to separate platelets from the rest of the blood, providing a boost of platelets, leukocytes and stem cells at the site in order to promote healing.

Platelets contain growth factors which aid in healing, however recent experiments have shown that leukocytes are also required for healing and regeneration as they help in sustaining the platelets.⁴ Cell-to-cell communication required for regeneration² and, apart from platelets, they also release certain growth factors such as VEGF, PDGF and TGF-⁵ which are needed for regeneration. It has not been established whether conventional PRF contains leukocytes; however experiments have shown that APRF is a rich source of leukocytes which are responsible for the advantage of its use over conventional PRF. Usually for such large bony lesions such as the one described in this case, a bone graft along with growth factors could have been used, but if APRF can enhance healing then it can be used in places of bone graft for regeneration, reducing the financial burden on the patient.

The results of bone healing in this case are consistent with the results shown by Malik *et al.*,⁶ and Subramaniam *et al.*,⁷ where healing was faster in bony defects where platelet-rich plasma (PRP) was used. However these authors have used PRP which has a lower concentration of growth factor content as compared to APRF. In a study by Masuki *et al.*,⁸ authors state that APRF contains

the maximum concentration of growth factors and listed all the available platelet concentrate preparations in the descending order of growth factors concentration as A-PRF U CGF > PRP >> PRGF. The same authors also stated that both A-PRF and CGF preparations contain significant amounts of growth factors, and thus, not only function as a scaffold but also as a reservoir of growth factors to be delivered at the site of application.^{8,9}

Keeping results of the aforementioned study in consideration, the authors of the present study decided to use APRF instead of PRP, with CBCT results after 6 months showing a significant reduction in the size of the bony lesion, along with continuously growing bone density, which is expected to continue to increase over time. A CBCT was obtained at 6 months and not at 9 or 12 months as, according to Frost,^{9,11} who first reported 'bone sigma', the complete cycle of bone resorption and deposition is 4-6 months.

However in the present case complete healing of the lesion had not taken place as it depends upon the size of the bony cavity;

based on these clinical and radiographic observations, post-op CBCT-PAI^{10,11} score can be reported as 2, where periapical radio-lucency with the major diameter is 1 mm-2 mm as compared to pre-op CBCT-PAI of 4, where periapical radiolucency with the major diameter is 4 mm-8 mm. Additionally, APRF is also used in periodontics and oral surgery for gum recession, in-trabony defects and healing sockets, and most recently it has also been used in cases of plastic and reconstructive surgery in burns and ulcers.^{12,13}

CONCLUSION

This case report shows APRF helps in faster healing; however it also depends upon the size of the bony lesion and the amount of APRF used. The limitation of this study is a short post-op follow up of 6 months, in which time frame complete bone healing was not observed. However significant improvement in CBCT-PAI scores denote an increase in bone density after complete enucleation of the cyst and with using APRF alone.

CONFLICT OF INTERESTS

The authors declare no conflict of interest.

ETHICS APPROVAL

Informed consent was provided by the patient

FUNDING

None.

AUTHORS' CONTRIBUTIONS

Gupta R: Conceptualization; investigation; methodology; writing - original draft; writing - review and editing.

Shukla S: Supervision; validation; visualization

ACKNOWLEDGEMENTS

None.

ORCID

Ravi Gupta

 0000-0002-1735-7247

Sagrika Shukla

 0000-0001-7751-3101

PUBLISHER'S NOTE

All statements expressed in this article are those of the authors alone and do not necessarily represent those of the publisher, editors, and reviewers.

COPYRIGHT

This is an open-access article distributed under the terms of the [Creative Commons Attribution License \(CC BY 4.0\)](https://creativecommons.org/licenses/by/4.0/). The use, distribution or reproduction in other forums is permitted, provided the original author(s) and the copyright owner(s) are credited and that the original publication in this journal is cited, in accordance with accepted academic practice. No use, distribution or reproduction is permitted which does not comply with these terms. © 2023.



PEER REVIEW

This manuscript was evaluated by the editors of the journal and reviewed by at least two peers in a double-blind process.

PLAGIARISM SOFTWARE

This manuscript was analyzed by Turnitin's Original plagiarism detector software. Analysis report of document (ID 4418d9fbabd2ed9122b3be2e492410c064cdee).

ISSN Print 0719-2460 - ISSN Online 0719-2479.

<https://www.joralres.com/index.php/JOralRes/issue/archive>

REFERENCES.

1. Rozman P, Bolta Z. Use of platelet growth factors in treating wounds and soft-tissue injuries. *Acta Dermatovenerol Alp Pannonica Adriat.* 2007;16(4):156-65. PMID: 18204746.
2. Choukroun J, Ghanaati S. Reduction of relative centrifugation force within injectable platelet-rich-fibrin (PRF) concentrates advances patients' own inflammatory cells, platelets and growth factors: the first introduction to the low speed centrifugation concept. *Eur J Trauma Emerg Surg.* 2018;44(1):87-95. doi: 10.1007/s00068-017-0767-9. Epub 2017 Mar 10. PMID: 28283682; PMCID: PMC5808086.
3. Henein C, Bhatia SK, Drage N. The Use of Cone Beam Computed Tomographic Imaging in a Paediatric Dentistry Department. *Oral.* 2021; 1(2):45-55.
4. Gordon S. Alternative activation of macrophages. *Nat Rev Immunol.* 2003;3(1):23-35. doi: 10.1038/nri978. PMID: 12511873.
5. Lucas T, Waisman A, Ranjan R, Roes J, Krieg T, Müller W, Roers A, Eming SA. Differential roles of macrophages in diverse phases of skin repair. *J Immunol.* 2010;184(7):3964-77. doi: 10.4049/jimmunol.0903356. Epub 2010 Feb 22. PMID: 20176743.
6. Malik AH, Tabasum R, Ahmad M, Shah AA, Ahmad I. Autogenous platelet rich plasma in healing of bone defects. *World J Med Medic Sci Res.* 2013; 1:82-4.
7. Subramaniam P, Kumar K, Ramakrishna T, Bhadranna A. Bone regeneration with plasma-rich-protein following enucleation of traumatic bone cyst. *Eur J Dent.* 2013;7(3):377-381. doi: 10.4103/1305-7456.115427. PMID: 24926221; PMCID: PMC4053630.
8. Masuki H, Okudera T, Watanebe T, Suzuki M, Nishiyama K, Okudera H, Nakata K, Uematsu K, Su CY, Kawase T. Growth factor and pro-inflammatory cytokine contents in platelet-rich plasma (PRP), plasma rich in growth factors (PRGF), advanced platelet-rich fibrin (A-PRF), and concentrated growth factors (CGF). *Int J Implant Dent.* 2016;2(1):19. doi: 10.1186/s40729-016-0052-4. Epub 2016 Aug 22. PMID: 27747711; PMCID: PMC5005757.
9. Frost HM. Bone remodeling dynamics. Springfield, Illinois, Charles C Thomas Company, 1963.
10. Esposito S, Cardaropoli M, Cotti E. A suggested technique for the application of the cone beam computed tomography periapical index. *Dentomaxillofac Radiol.* 2011;40(8):506-12. doi: 10.1259/dmfr/78881369. PM ID: 22065800; PMCID: PMC3528160.
11. Estrela C, Bueno MR, Azevedo BC, Azevedo JR, Pécora JD. A new periapical index based on cone beam computed tomography. *J Endod.* 2008;34(11):1325-1331. doi: 10.1016/j.joen.2008.08.013. Epub 2008 Sep 17. PMID: 18928840.
12. Gollapudi M, Bajaj P, Oza RR. Injectable Platelet-Rich Fibrin - A Revolution in Periodontal Regeneration. *Cureus.* 2022;14(8):e28647. doi: 10.7759/cureus.28647. PMID: 36196318; PMCID: PMC9525133.
13. Farshidfar N, Jafarpour D, Firoozi P, Sahmeddini S, Hamedani S, de Souza RF, Tayebi L. The application of injectable platelet-rich fibrin in regenerative dentistry: A systematic scoping review of In vitro and In vivo studies. *Jpn Dent Sci Rev.* 2022;58:89-123. doi: 10.1016/j.jdsr.2022.02.003. Epub 2022 Mar 29. PMID: 35368368; PMCID: PMC8971935.