

Oral Pemphigus treated with minipulse therapy.

Kundoor Vinay Kumar Reddy,¹ Kotya Naik Maloth,¹
Tejaswini Meesala¹ & Moni Thakur.²

Affiliations: ¹Dept. of Oral Medicine and Radiology, Mamata Dental College and Hospital, Khammam, Telangana, India. ²Dept. of oral and maxillofacial pathology, Mamata dental college, Khammam, Telangana, India.

Corresponding author: Kotya Naik Maloth. Mamata dental college and hospital, Giriprasad Nagar, Khammam-507002, Telangana, India. Phone: (91) 9885617131. E-mail: dr.kotyanaik.maloth@gmail.com

Receipt: 07/10/2018 **Revised:** 10/26/2018
Acceptance: 10/24/2018 **Online:** 12/17/2018

Conflict of interests: The authors declare no conflict of interests.

Ethics approval: Ethical approval granted by the Research and Ethics committee of the Mamata Dental College and Hospital, Telangana, India.

Funding: None.

Authors' contributions: All authors contributed to the work.

Acknowledgements: None.

Cite as: Kumar Reddy KV, Maloth KN, Meesala T & Thakur M. Oral Pemphigus Treated with Minipulse Therapy. J Oral Res 2018; 7(9):432-436.
[doi:10.17126/joralres.2018.087](https://doi.org/10.17126/joralres.2018.087)

Abstract: Pemphigus is a chronic potentially fatal autoimmune disorder that causes blisters and erosions of the skin and oral mucous membrane. Most of the cases present oral manifestations as the first clinical sign along with dermal lesions. Only 0.5 to 3.2 of cases are reported each year per 1,000,000 population with oral manifestations without dermal participation, and is at times difficult to diagnose. We report a case of oral pemphigus vulgaris in a 20 year old female patient without dermal manifestations treated with oral mini pulse therapy.
Keywords: Autoimmune diseases; blister, pulse therapy; pemphigus.

INTRODUCTION.

Pemphigus is a chronic inflammatory mucocutaneous autoimmune disorder, characterized by blisters and erosions of the skin and the mucous membrane.¹ 0.5 to 3.2 cases are reported each year per 1,000,000 population with oral manifestations without dermal participation.

Pemphigus is most commonly seen in the 5th and 6th decade of life, and rarely seen in children, and has a predominance in females with a male to female ratio of 1:2.^{2,3} *Pemphigus Vulgaris (PV)*, *Pemphigus Vegetans*, *Pemphigus Foliaceus*, *Pemphigus Erythematous*, *Paraneoplastic Pemphigus (PNP)* and drug related pemphigus are major variants of pemphigus. Eighty percent of cases are encounter correspond to PV, initially affects the oral mucosa, without any cutaneous involvement, and can be difficult to diagnose.⁴ Here, we report a case of oral PV in a 20 year old female patient without dermal manifestations.

CASE REPORT.

A 20-year-old female patient reported to the *Department of Oral Medicine and Radiology of the Mamata Dental College and Hospital* with the chief complaint of ulcers in the mouth for the past two months. History revealed that first she noticed difficult swallowing while eating, whose severity had progressively increased. Later, she had noticed ulcers in the mouth that bled on brushing and also gave a history of increased salivation in the morning. The patient did not report any skin lesions. Her medical and family history was noncontributory.

Extra oral examination revealed palpable right and left submandibular lymph nodes, which were enlarged, mobile and tender. Intra oral examination revealed ulcerative lesions present bilaterally on the buccal mucosa along the line of occlusion extending antero-posteriorly from

the retrocommisural areas to the retromolar trigone region. The lesions were irregular in shape covered by a pseudo-membrane and an erythematous surrounding area. Bleeding was evident on palpation. Erosive lesions were observed involving the posterior hard plate and soft palate. There were diffuse areas of erosions covered by a pseudo-membrane at some sites with positive Nikolsky's sign. Generalised gingival inflammation with bleeding on probing was present. (Figure 1)

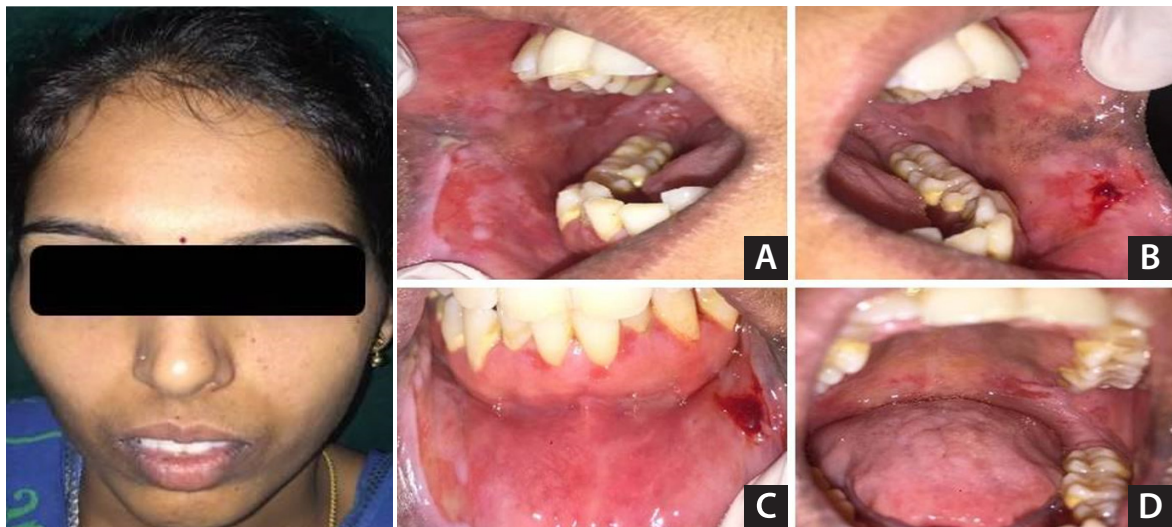
Based on the clinical examination and the patient's history pemphigus was diagnosed, with a differential diagnosis of *pemphigus vulgaris*, mucous membrane pemphigoid, bullous lichen planus, paraneoplastic pemphigus, chronic ulcerative stomatitis, recurrent herpes lesions in immunocompromised patients and erythema multiforme.

Routine baseline investigations such as hematological and biochemical investigations were within normal limits. Incisional biopsy was performed and histopathological examination revealed parakeratinized stratified squamous epithelium with intra-epithelial blister formation. Split area was covered by a thick area of fibrinous exudate consisting of inflammatory cells. Occasional giant cells were seen in the split area. (Figure 2)

Chronic inflammatory cell infiltrate in the sub-epithelial and perivascular region was evident. Based on the histopathological findings, a final diagnosis of pemphigus vulgaris was made.

The treatment plan comprised of oral prednisolone (Wysolone, Pfizer) 30mg/day for four days along with a multi-vitamin and topical analgesic. On the first follow-up, the patient had 50% reduction in symptoms with

Figure 1. Intra- and Extra-oral signs at presentation.



A. Ulcerative lesions on right buccal mucosa. **B.** Ulcerative lesions on left buccal mucosa. **C.** Desquamative gingivitis. **D.** Erosive lesions involving hard and soft palate.

Figure 2. Histopathology picture shows suprabasilar split with acantholysis of keratinocytes.

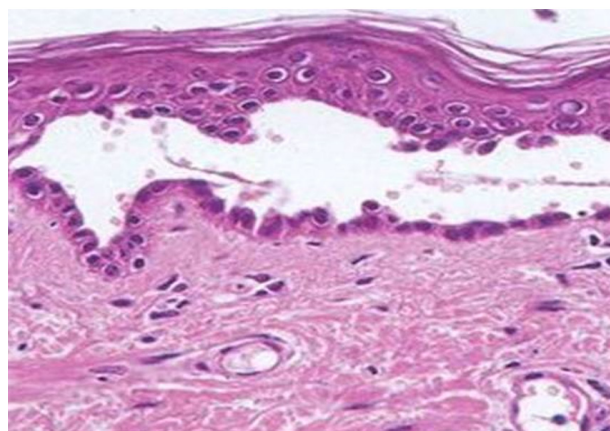
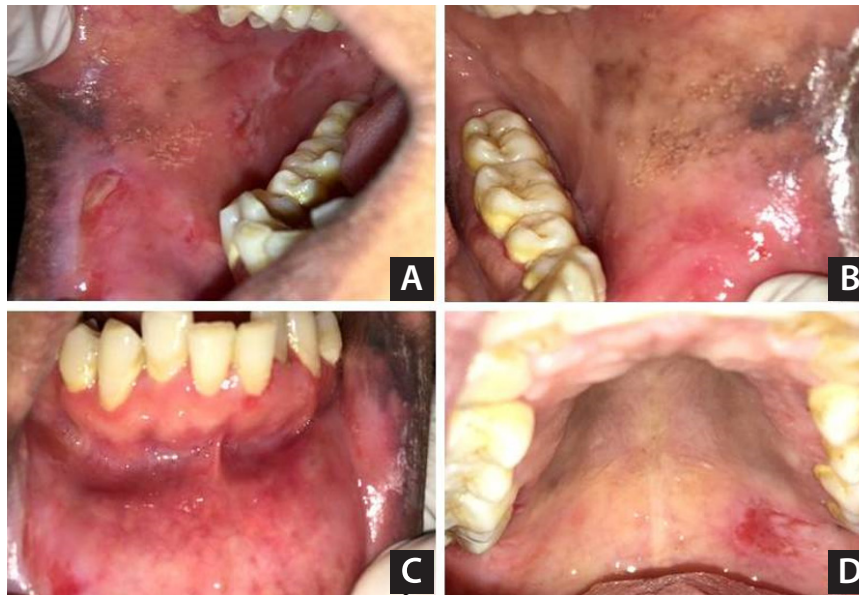
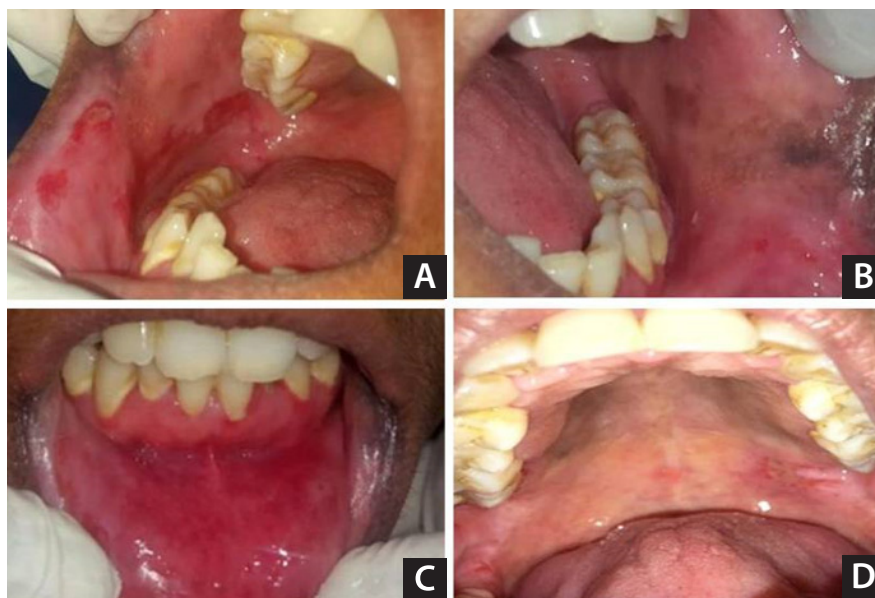


Figure 3. Post-treatment follow up after 10 days of treatment, intra oral examination showed 70% remission of the lesions.



A. Remission of the lesions on right buccal mucosa. **B.** Remission of the lesions on left buccal mucosa. **C.** Healing of the desquamative gingivitis. **D.** Remission of the lesions on posterior hard plate and soft palate.



A. Partial remission of the lesions on right buccal mucosa. **B.** Complete remission of the lesions on left buccal mucosa. **C.** Complete healing of the desquamative gingivitis. **D.** Complete remission of the lesions on posterior hard plate and soft palate.

partial healing of lesions; erythema and inflammation in relation to ulcers had reduced. The dose of Wysolone was tapered to 20mg/day for the next four days, and 0.1% triamcinolone acetonide topical ointment was also prescribed to the patient. On the second follow-up, a further 20% reduction in symptoms was noticed compared to the first follow-up visit, and a reduction in

the number of lesions was noted.

The dose of prednisolone was tapered to 10mg/day for 4 four days. (Figure 3) On the third follow-up, symptoms were completely reduced. The dose of prednisolone was further tapered to 5mg/day for the next three days. On the final visit, complete regression of lesions were noticed. (Figure 4)

DISCUSSION.

Pemphigus includes a group of potentially fatal autoimmune mucocutaneous blistering disorders, characterized by acantholysis. The autoantibodies (IgG) target desmoglein 3, a transmembrane glycoprotein found in the desmosome involved in intercellular adhesion.⁵ Most variants of pemphigus are classified as subtypes *pemphigus vulgaris* (PV), *pemphigus foliaceus* (PF), *pemphigus erythematosus* (PE) and *paraneoplastic pemphigus* (PNP).⁵

Clinically, it is most commonly seen in the 5th and 6th decade of life, and rarely seen in children with a predominance in females with a male to female ratio of 1:2.^{2,3} 70-90% of the cases present oral manifestations as the first clinical sign,⁶ primarily involving the buccal mucosa, pharynx and gingiva. The cutaneous part involving the chest, face, scalp, upper back, and areas of trauma are common sites.⁷ The present case was consistent with the literature except regarding age, which was younger in the present case, at 20 years old and with no cutaneous involvement.

Thin walled bulla arising on the skin or oral mucosa is the classical lesion of pemphigus with a characteristic positive Nikolsky's sign, which is also found in toxic epidermal necrolysis (TEN) and scalded skin syndrome (both acute lesions), as well as in mucous membrane pemphigoid.⁸ The lesions of pemphigus should be differentiated from acute viral infections and other lesions seen in immunocompromised patients such as atypical ulcers lasting for weeks to months if undiagnosed or untreated.

The diagnosis of such clinically suspicious lesions of pemphigus can be best confirmed with a combination of a thorough patient history, laboratory investigations and histopathological features.⁹ A fresh vesicle or the edge of a blister less than 24 hours old, accompanied by adjacent normal skin or mucosa, should be obtained for histopathology or direct immunofluorescence (DIF).⁹

The key histological feature of pemphigus is an intra-epidermal split with the loss of adhesion and separation of normal appearing keratinocytes referred to as acantholysis. In PV, the histology shows suprabasilar split with acantholysis of keratinocytes, which helps to distinguish from other conditions such as mucous membrane pemphigoid, bullous lichen planus and chronic ulcerative

stomatitis. In PV, DIF will be positive for intercellular IgG deposition and C3 antibodies involving the entire perilesional skin or mucosa.⁹

In the present case, the patient had no history of immunocompromising disorders and was not taking any drugs to treat any such disorders. Indirect immunofluorescence has a lower sensitivity than DIF, but it may be useful in cases where it is difficult to obtain a biopsy.⁵ The management of all variants of pemphigus is done in two phases: the loading phase to control the disease, followed by the maintenance phase to induce disease remission.¹⁰ Corticosteroids are considered as the gold standard in the management of all variants of pemphigus, and were first used by Thorn *et al.*,¹¹ and further popularized by Costello *et al.*,¹² later in that decade, and Lever *et al.*,¹³

With the use of these drugs a drastic decrease in the mortality rate associated with PV occurred, estimated to be 5 to 15%.¹⁴ Topical agents are preferred over systemic drugs except during acute exacerbations. Topical corticosteroids for a short duration are safe, but prolonged use can lead to side effects such as secondary candidiasis and atrophy of the oral mucosa.¹⁵ Systemic corticosteroids are recommended during acute conditions and for persistent erosions, at high doses (prednisolone 30-80mg/day) for a short duration (2-3 weeks), known as pulse therapy.¹⁶ However, such regimens are also not free of side effects. Early diagnosis requires lower doses of steroids for shorter periods to control the condition.

Pulse therapy is defined as discontinuous or intermittent intravenous infusions of very high doses of drugs over a short time. The concept of pulse therapy was first introduced in 1969 by Kauntz *et al.*¹⁷

In India, Dr. JS Pasricha *et al.*¹⁸ was the first to use pulse therapy for the management of Reiter's diseases in 1984. Pulse therapy has been widely used in the treatment of various immunological related disorders. The drugs used in pulse therapy include corticosteroids, immunosuppressive drugs, antifungals and antibiotics.¹⁵ To overcome or minimize these limitations without compromising efficacy, the concept of oral minipulse (OMP) therapy was designed. In the form of OMP therapy, corticosteroids have shown efficacy with few and acceptable side effects.¹⁹

Early diagnosis with initial daily doses of prednisone equivalent to 0.5 to 2.0mg/kg is recommended to control the

condition, as well to prevent serious fatal complications.²⁰ In the present case oral prednisolone 30 mg/day for four days along with a multi-vitamin and topical analgesic were prescribed on first visit, which resulted in a 50% reduction in symptoms with partial healing of lesions.

The dose of prednisolone was tapered to 20mg/day for the next four days, resulting in a 20% reduction in symptoms compared to the first follow-up and further reduction in the lesions. The prednisolone dose was further tapered to 10mg/day for following four days. On the third follow-up, symptoms were completely reduced. The prednisolone dose was further tapered to 5mg/day for the next three days. On final visit, complete regressions of lesions were noticed. The patient was further followed for one year, and no recurrence of lesions or any complications were noted.

REFERENCES.

1. Arpita R, Monica A, Venkatesh N, Atul S, Varun M. Oral Pemphigus Vulgaris: Case Report. *Ethiopian J Health Sci.* 2015;25(4):367-72.
2. Shamim T, Varghese V, Shameena PM, Sudha S. Pemphigus vulgaris in oral cavity: clinical analysis of 71 cases. *Med Oral Patol Oral Cir Bucal.* 2008;13(10):E622-6.
3. Williams DM. Vesiculobullous mucocutaneous disease: pemphigus vulgaris. *J Oral Pathol Med.* 1989;18(10):544-53.
4. Scully C, Paes De Almeida O, Porter SR, Gilkes JJ. Pemphigus vulgaris: the manifestations and long-term management of 55 patients with oral lesions. *Br J Dermatol.* 1999;140(1):84-9.
5. DiMarco C. Pemphigus: Pathogenesis to Treatment. *R I Med J.* 2016;99(12):28-31.
6. Dagistan S, Goregen M, Miloglu O, Cakur B. Oral pemphigus vulgaris: a case report with review of the literature. *J Oral Sci.* 2008;50(3):359-62.
7. Di Zenzo G, Amber KT, Sayar BS, Müller EJ, Borradori L. Immune response in pemphigus and beyond: progresses and emerging concepts. *Semin Immunopathol.* 2016;38(1):57-74.
8. Urbano FL. Nikolsky's Sign in Autoimmune Skin Disorders. *Hospital Physician.* 2001:23-4.
9. Hertl M, Jedlickova H, Karpati S, Marinovic B, Uzun S, Yayli S, Mimouni D, Borradori L, Feliciani C, Ioannides D, Joly P, Kowalewski C, Zambruno G, Zillikens D, Jonkman MF. Pemphigus. S2 Guideline for diagnosis and treatment--guided by the European Dermatology Forum (EDF) in cooperation with the European Academy of Dermatology and Venereology (EADV). *J Eur Acad Dermatol Venereol.* 2015;29(3):405-14.
10. Harman KE, Albert S, Black MM, British Association of Dermatologists. Guidelines for the management of pemphigus

CONCLUSION.

Pulse therapy is a promising treatment modality for life threatening auto immune disorders. It has been proved successful for the treatment of PV without any or with acceptable side effects only. The present case illustrates that OMP therapy is an appropriate treatment modality to manage pemphigus lesions. The advantages of OMP over conventional therapy are its convenient dosage schedule, efficacy, minimal or acceptable side-effects without any complications. Hence, OMP therapy can be employed as a routine treatment modality for PV as it offers a non-invasive treatment mode that yields significant improvements in the clinical condition of patient. However, long term follow up is mandatory to compare the incidence of malignancy in patients receiving pulse doses of immunosuppressive drugs.

- vulgaris. *Br J Dermatol.* 2003;149(5):926-37.
11. Thorn GW, Forsham PH, Frawley TF, Hill SR Jr, Roche M, Staehelin D, Wilson DL. The clinical usefulness of ACTH and cortisone. *N Engl J Med.* 1950;242(22):865-72.
12. Costello MJ, Jaimovich L, Dannenberg M. Treatment of pemphigus with corticosteroids; study of fifty-two patients. *J Am Med Assoc.* 1957;165(10):1249-55.
13. Lever WF, White H. Treatment of pemphigus with corticosteroids: Results obtained in 46 patients over a period of 11 years. *Arch Dermatol.* 1963;87:52-66.
14. Bystryn JC. Adjuvant therapy of pemphigus. *Arch Dermatol.* 1984;120(7):941-51.
15. Kaul R, Sanjay CJ. Review on Pulse Therapy: A Novel Approach in the Treatment of Pemphigus Vulgaris. *J Indian Acad Oral Med Radiol.* 2010;22(4):211-4.
16. Maloth KN, Sunitha K, Boyapati R, Kumar DRS. Bullous Lichen Planus treated with Oral Minipulse Therapy: A Rare Case Report. *J Clin Diagn Res.* 2014;8(12):ZD17-9.
17. Kauntz SL, Cohn R. Initial treatment of renal allografts with large intra renal doses of immunosuppressive drugs. *Lancet.* 1969;293:338-40.
18. Pasricha JS, Gupta R. Pulse therapy with dexamethasonecyclophosphamide in pemphigus. *Indian J Dermatol Venereol Leprol.* 1984;50:199-203.
19. Malhotra AK, Khaitan BK, Sethuraman G, Sharma VK. Betamethasone oral mini-pulse therapy compared with topical triamcinolone acetonide (0.1%) paste in oral lichen planus: A randomized comparative study. *J Am Acad Dermatol.* 2008;58(4):596-602.
20. Fellner MJ, Sapadin AN. Current therapy of pemphigus vulgaris. *Mt Sinai J Med.* 2001;68(4-5):268-78.