

Bilateral hyperplasia of the coronoid process. Clinical case report with unusual presentation and literary review.

Alvaro Villegas Cisneros,¹ Ernesto Miranda Villasana¹
& Eduardo Varela Ibáñez.²

Affiliations: ¹Maxillofacial Surgery ISSSTE Hospital Reg. Gral. I. Zaragoza, Mexico.²Head of the Craniofacial Service and Division of Oral Health. Hospital del Niño DIF, Pachuca, Mexico.

Corresponding author: Alvaro Villegas Cisneros. Calz. Ignacio Zaragoza 1711, Ejército Constitucionalista, Chinam Pac de Juárez, 09220 Ciudad de México, CDMX, Mexico. E-mail: arthanyz@hotmail.com

Receipt: 07/11/2018 **Revised:** 08/20/2018
Acceptance: 10/19/2018 **Online:** 12/19/2018

Abstract: The formation of a new joint between a pathologically enlarged coronoid process and the body of the malar bone is known as Jacob's disease. Hyperplasia of the coronoid process was first described in 1853 by von Langenbeck, and it was not until 1899 when Oscar Jacob described the disease that was named after him. Jacob's disease is an uncommon entity with only a few cases documented in the literature. The condition manifests at first with progressive limitation of the oral opening and facial asymmetry. The pain is infrequent and mainly affects young patients. Temporal muscle hyperactivity, cranial trauma, chronic displacement of the ipsilateral temporomandibular joint, endocrine stimuli and genetic alterations have been postulated as possible factors. The definitive diagnosis is by histopathology and it is necessary that bone hyperplasia is confirmed, as well as the presence of cartilage and synovial capsule forming the new joint between the malar bone and the coronoid process. We present a 10-year-old patient with a history of childhood trauma in the left preauricular region. It presented to our service with a history of progressive limitation of the oral opening. Computed tomography (CT) revealed an elongation of the bilateral coronoid process, in contact with homolateral zygomatic bone, causing its deformation. Surgery under general anesthesia was performed through the intraoral vestibular route. Histopathology confirmed the diagnosis of Jacob's disease. We review the literature regarding the etiology, pathogenesis, clinical characteristics, diagnosis and treatment of this condition.

Keywords: *Hyperplasia; coronoid process; Jacob's disease; temporomandibular joint disorders; coronoidectomy.*

Conflict of interests: The authors declare no conflict of interests.

Ethics approval: Ethical approval granted by the Hospital del Niño Dif Hidalgo, in Pachuca, Mexico.

Funding: No funding.

Authors' contributions: All authors contributed to the review and editing of this article.

Acknowledgements: None.

Cite as: Cisneros AV, Villasana EM & Ibáñez EV. Dental Implant Placement with Flapless and Flapped Technique: A Systematic Review. *J Oral Res* 2018; 7(9):437-441.
doi:10.17126/joralres.2017.084

INTRODUCTION.

Coronoid hyperplasia is a very uncommon pathological condition, characterized by a disproportionate and progressive growth, both in volume and in height, of the unilateral or bilateral mandibular coronoids.¹

This phenomenon was first described by von Langenbeck² in 1853, and widely published in 1963 by Rowe,³ who describes it as an abnormality of the coronoid processes, dividing them into two types, caused either by development or by neoplastic changes. The neoplasms are characterized as unilateral while those of development are bilateral, which is why neoplastic or unilateral Jacob's disease whose symptoms are similar and in which, in addition to coronoid hyperplasia, synovial joint formation occurs between the coronoid process and ipsilateral zygomatic bone, should be excluded as coronoid process hyperplasia

(CPH) since they present a different microstructure.^{3,4}

Jacob's⁵ disease is a rare condition that consists of the formation of a pseudoarticulation between the enlarged coronoid process and the internal face of the zygomatic bone. It was first described by Jacob in 1895. Clinically both entities present as a progressive and asymptomatic limitation of the oral opening, without abnormalities in occlusion. This limitation of the mandibular movements is secondary to a mechanical blockage of the coronoid processes that occurs behind the body of the malar bone, causing a temporomandibular pseudo-ankylosis.

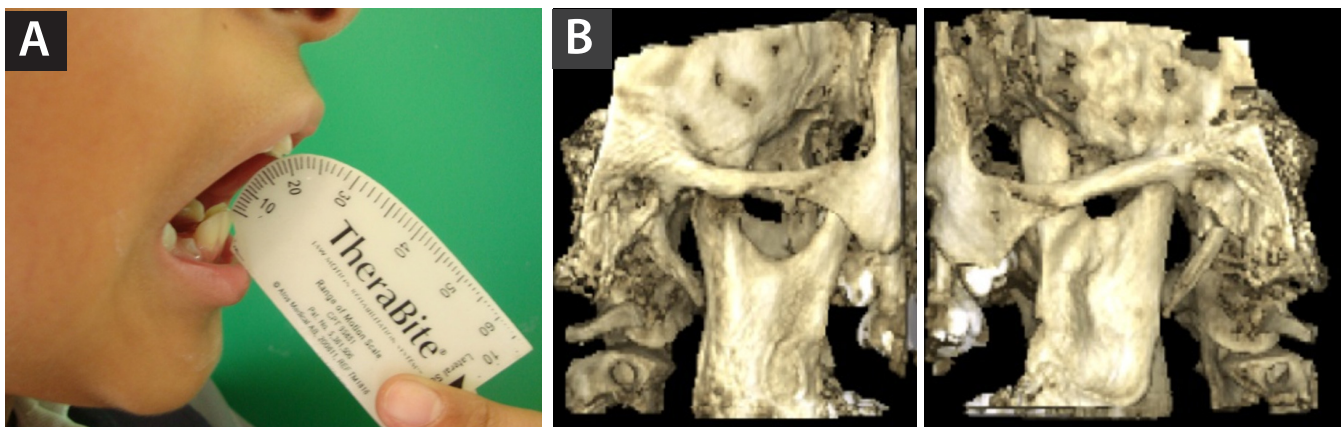
This condition can become so severe that it can compromise the aerodigestive tract resulting in symptoms of dyspnea, delayed mandibular growth, muscular atrophy, and difficulty feeding.^{1,6,7}

The definitive diagnosis is obtained through a complete imaging study of the region, computed

tomography, and complementary open-mouth magnetic resonance as well as the use of the Levandoski analysis, where the height is measured from the lowest part of the angle mandibular to the upper limit of the mandibular condyle and the tip of the coronoid process. The height of the coronoid process (between 12mm and 13mm) should be less than that of the condyles,^{6,8} but in CPH the coronoids measure more than 20mm.^{1,6-8}

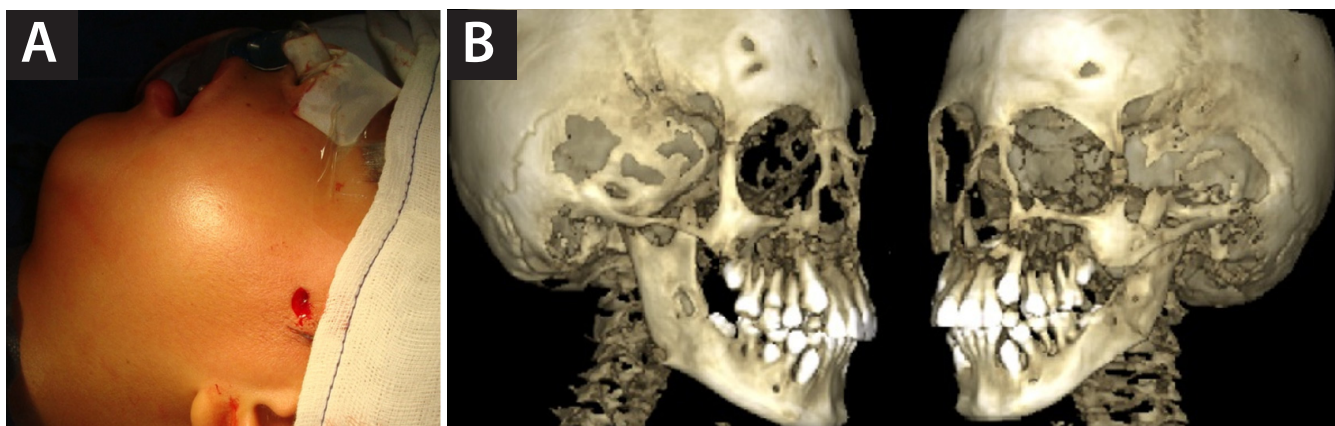In patients with CPH, which essentially presents a mechanical problem such as limited mouth opening, a surgical treatment is performed with prolonged postoperative physiotherapy. The standard surgical treatment for CPH is the correction of coronoid-malar interference by a coronoidectomy via an intraoral approach, although coronal and submandibular approaches have also been used, although with increased morbidity and aesthetic sequelae due to scarring.

Figure 1. Study of patient and computed tomography.



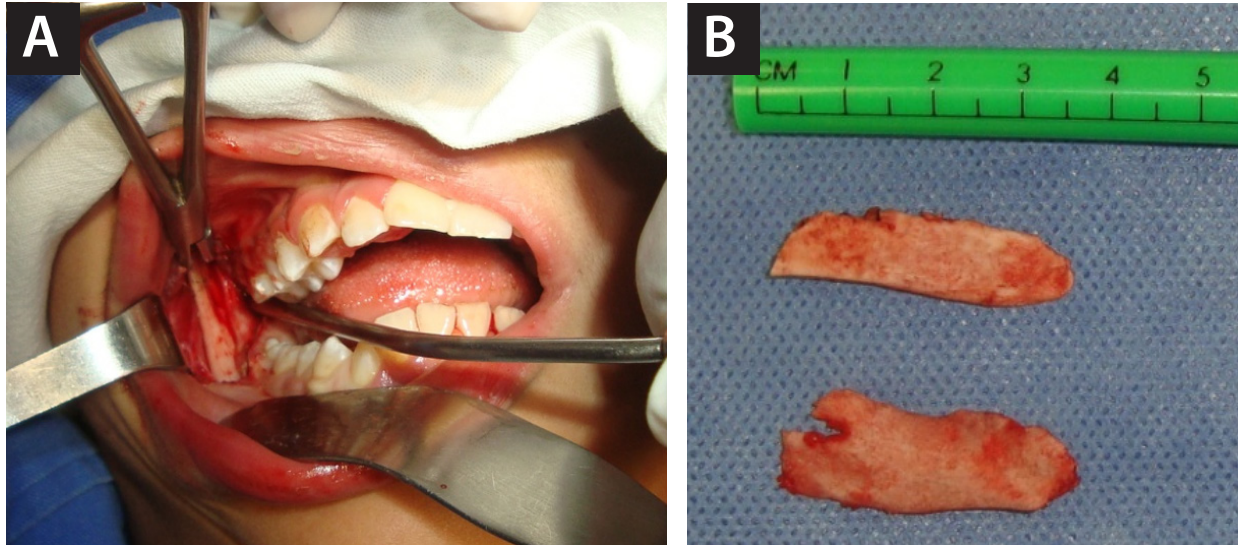
A. Initial oral opening 19mm. B. CT reconstruction, hyperplastic coronoid processes.

Figure 2. Transcutaneous approach and Coronoid osteotomy.



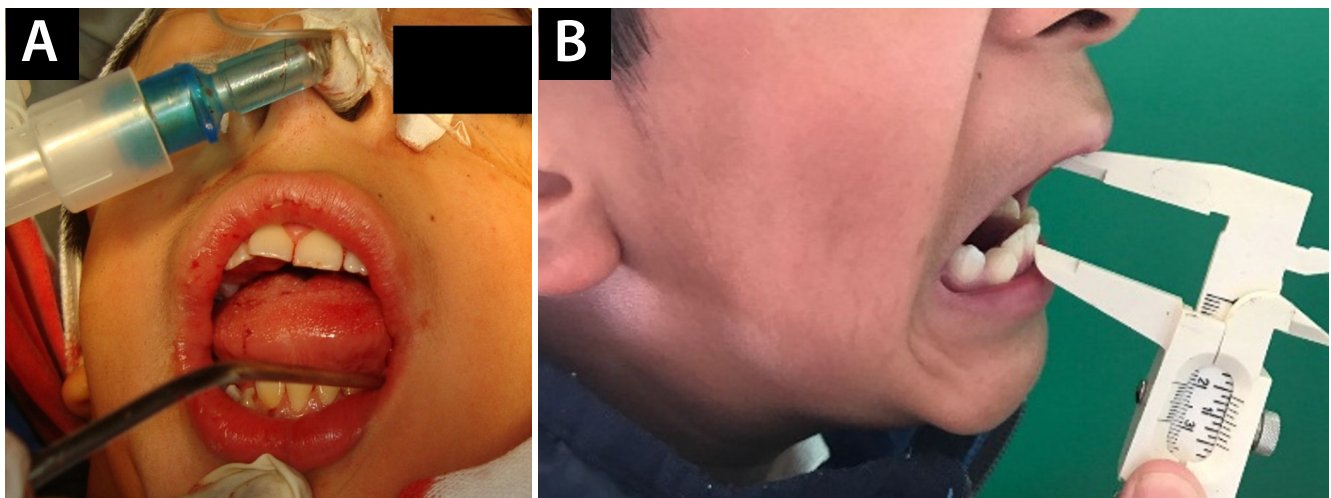
A. Transmalar incision. B. CT reconstruction, hyperplastic coronoid processes.

Figure 3. Transcutaneous approach and Coronoid osteotomy.



A. Intraoral approach. B. Bilateral coronoidectomy.

Figure 4. Transoperative course and postoperative control photograph.



A. Transoperative oral opening. B. 32mm postoperative oral opening at 15 days.

CASE REPORT.

A 10-year-old male patient referred by a dentist who, during routine evaluation, detected severe limitations on oral opening. The relatives reported "*believing that their oral opening was normal, as a child*", so they presented to the maxillofacial surgery service of the Hospital del Niño Dif Hidalgo, in Pachuca, Mexico. Clinically healthy systemically without any hereditary family history; during clinical examination directed facial asymmetry at the expense of dentofacial deformity class II, oral opening of 19mm (Figure 1. A), and limited mandibular dynamics was noted. An elongated left coronoid process was identified in a panoramic radiograph, so a computed tomography

with three-dimensional reconstruction (3D CT scan) was requested, which confirmed the bilateral coronoid hyperplasia. This process produced a mechanical block on the inside of the body of the homolateral malar bone, with signs of bone remodeling, contacting both structures during the oral opening. (Figure 1. B) According to the radiographic findings, a hyperplasia of the mandibular coronoid process was suspected in association with TMJ dysfunction. The patient underwent a coronoidectomy under general anesthesia using a transoral approach. A synovial joint formation was identified between said elongated coronoid process and the internal cortex of the left side of the zygomatic body, and it was decided to perform a transcutaneous

approach adjacent to the zygomatic arch with an incision of approximately 5mm (Figure 2. A) in order to project intraorally the segment, since the apparent mechanical block originated from the posterior aspect of the zygomatic bone. (Figure 2. B) Coronoid osteotomy was performed and a regularization of the malar bone by means of a rasp. The coronoid processes obtained measured approximately 30mm on the right side and 35mm on the left in length. (Figure 3. A) The resected coronoids presented a small nodular structure of 0.5 cm in diameter on its articular surface. (Figure 3. B) A maximum oral opening of 35 mm was noted during the procedure. (Figure 4. A) Histopathology confirmed the presence of hyaline structures and remains of the synovial capsule, confirming the diagnosis of Jacob's disease. The postoperative control photograph is presented at 15 days. (Figure 4. B)

The functional orthopedic treatment started with immediate and aggressive physiotherapy 24 to 72 hours after surgery, after the postoperative pain had decreased, with the aim of performing opening and closing movements with the support of mouth openers; movements of laterality and forced protrusion were instructed to be also performed with the help of a relative.

Physiotherapy was indicated for 10 min, 4 to 5 times a day, simulating the effect of an exercise regimen for the chewing muscles inside the mouth. The patient was referred to the maxillary orthopedics service to follow up and implement the corresponding device.

DISCUSSION.

Symptomatic hyperplasia of the coronoid process is an infrequent condition. Since the first case reported by Langenbeck, there has been much confusion regarding the nature and pathogenesis of this condition.

There are diverse hypotheses regarding the genesis of this condition: The hyperactivity of the temporal muscle that is often present together with internal alterations of the TMJ which promotes hyperplasia through a reactive process in response to tendon attraction has been described by different authors as a relevant etiological factor. Furthermore, according to Isberg,⁹ CPH is the cause of trismus in approximately 5% of patients with such condition. However, this aspect is controversial

and not unanimously accepted.^{10,11} CPH does not have specific histological characteristics and the histological study of the hyperplastic coronoid processes only shows normal bone tissue.^{9,10}

Endocrine stimulation, increased temporal muscle activity, history of injury and inheritance have also been suggested as possible contributing factors to coronoid process hyperplasia, but the cause has not yet been clearly identified.¹²

Although there are not enough epidemiological data on the prevalence of this condition, asymptomatic cases are probably more frequent than previously thought. Honig examined the panoramic radiographs of a randomly selected sample of 2,000 patients and found a prevalence of 0.5%. A much lower prevalence of Jacob's disease should be expected.¹¹

The definitive diagnosis is histopathological. Hyperplasia of the coronoid process is not always synonymous with Jacob's disease, in which the coronoid process forms a pseudoarticulation with the internal surface of the malar bone and is accompanied by cartilaginous structures and the formation of a synovial capsule.¹³⁻¹⁶ Depending on the relationship between bone and cartilage, the diagnosis may be osteochondroma, osteoma, exostosis or hyperplasia.

Recurrence can be observed as a common finding after surgical treatment, for the most part this is due to the formation of scar tissue with subsequent fibrosis adjacent to the operated area. This is why the dynamic mandibular physiotherapy with a program of rehabilitation based on heat therapy and the use of functional orthopedic appliances to reduce postoperative fibrosis is important to maintain long-term stable results, with the aim of maintaining continuous activity of the neuromuscular system supporting the jaw. As well as the habilitation of the muscles involved in mastication, especially the anterior portion of the temporal muscle and the posterior portion of the masseter muscle, an effective therapy to increase the oral opening should be established.¹¹

Evidence indicated that early physiotherapy is essential, that rehabilitation exercises can be initiated immediately after surgery, and that they should be continued for at least three months, which is of great importance for a long-term satisfactory outcome.¹⁶⁻¹⁹

CONCLUSION.

Bilateral or unilateral coronary hyperplasia is one of the many pathologies that limit physiological oral opening. These pathologies are rare and their etiology has not yet been clearly explained.

REFERENCES.

1. Behrends CA, Fragoso GL. Hiperplasia de procesos coronoideos mandibulares: un nuevo tratamiento posquirúrgico. *Rev Esp Cir Oral Maxilofac.* 2015;37(2):93–8.
2. Von Langenbeck B. Angeborene Kleinheit der unterkiefer. *Langenbeck' archive.* 1861;1:451–5.
3. Rowe NL. Bilateral developmental hyperplasia of the mandibular coronoid process. A report of two cases. *Br J Oral Surg.* 1963;1:90–104.
4. Mulder CH, Kalaykova SI, Gortzak RA. Coronoid process hyperplasia: a systematic review of the literature from 1995. *Int J Oral Maxillofac Surg.* 2012;41(12):1483–9.
5. Jacob O. Une cause rare de constriction permanente des machoires. *Bull et Mem De la Societe Anatomique De Paris.* 1899;1:917–9.
6. Stopa Z, Wanyura H, Kowalczyk P. Coronoid-condylar index in assessing of mandibular coronoid hyperplasia. Preliminary results. *Adv Med Sci.* 2013;58(2):429–33.
7. Tavassol F, Spalthoff S, Essig H, Bredt M, Gellrich NC, Kokemüller H. Elongated coronoid process: CT-based quantitative analysis of the coronoid process and review of literature. *Int J Oral Maxillofac Surg.* 2012;41(3):331–8.
8. Kubota Y, Takenoshita Y, Takamori K, Kanamoto M, Shirasuna K. Levandoski panoramic analysis in the diagnosis of hyperplasia of the coronoid process. *Br J Oral Maxillofac Surg.* 1999;37(5):409–11.
9. Isberg A, Isacson G, Nah KS. *Oral Surg Oral Med Oral Pathol.* 1987;63(3):275–9.
10. Kursoglu P, Capa N. Elongated mandibular coronoid process as a cause of mandibular hypomobility. *Cranio.* 2006;24(3):213–6.
11. Hönig JF, Merten HA, Halling F, Korth OE. Röntgenologische Studie zur Häufigkeit der asymptomatischen Processus-coronoideus-Vergrößerung. *Schweiz Monatsschr Zahnmed.* 1993;103:281–4.
12. McLoughlin PM, Hopper C, Bowley NB. Hyperplasia of the mandibular coronoid process: an analysis of 31 cases and a review of the literature. *J Oral Maxillofac Surg.* 1995;53(3):250–5.
13. Tieghi R, Galiè M, Piersanti L, Clauser L. Bilateral hyperplasia of the coronoid processes: clinical report. *J Craniofac Surg.* 2005;16(4):723–6.
14. Escuder i de la Torre O, Vert Klok E, Mari i Roig A, Mommaerts MY, Pericot i Ayats J. Jacob's disease: report of two cases and review of the literature. *J Craniomaxillofac Surg.* 2001;29(6):372–6.
15. Capote A, Rodríguez FJ, Blasco A, Muñoz MF. Jacob's disease associated with temporomandibular joint dysfunction: a case report. *Med Oral Patol Oral Cir Bucal.* 2005;10(3):210–4.
16. Yoda T, Sato T, Abe T, Sakamoto I, Tomaru Y, Omura K, Hatano N, Takato T, Ishii Y. Long-term results of surgical therapy for masticatory muscle tendon-aponeurosis hyperplasia accompanied by limited mouth opening. *Int J Oral Maxillofac Surg.* 2009;38(11):1143–7.
17. Fernández Ferro M, Fernández Sanromán J, Sandoval Gutierrez J, Costas López A, López de Sánchez A, Etayo Pérez A. Treatment of bilateral hyperplasia of the coronoid process of the mandible. Presentation of a case and review of the literature. *Med Oral Patol Oral Cir Bucal.* 2008;13(9):E595–8.
18. Belmont-Laguna F, Sánchez-Matus L, Téllez-Rodríguez J, Ceballos-Hernández H. Terapia funcional en el postoperatorio de la anquilosis temporomandibular en pacientes pediátricos (1ª parte) *Acta Pediatr Mex.* 2007;28(3):111–7.
19. Puche M, Guijarro-Martínez R, Pérez-Herrezuelo G, Miragall L, Iglesias ME, Martínez-Costa C. The hypothetical role of congenital hypotonia in the development of early coronoid hyperplasia. *J Craniomaxillofac Surg.* 2012;40(6):e155–8.

Successful management requires the establishment of an accurate diagnosis and a therapeutic strategy that includes surgical treatment with dynamic physiotherapy and functional orthopedics in order to reduce recurrence as a postoperative sequela.