

Comparison of Ostene® and Bone wax on Bone Healing: A Comparative experimental study in rabbits.

Huda A. Salim.¹

Affiliations: ¹Department of Oral and Maxillo-facial Surgery, College of Dentistry, University of Mosul, Iraq.

Corresponding author: Huda A. Salim. Mosul 41002, Iraq. E-mail: hudaakram81@yahoo.com

Receipt: 09/20/2018 **Revised:** 11/06/2018
Acceptance: 11/07/2018 **Online:** 12/13/2018

Conflict of interests: The author declare no conflict of interests.

Ethics approval: Ethical approval granted by the Research and Ethics College of Dentistry, University of Mosul, Iraq.

Funding: The research is self-funded.

Authors' contributions: All authors contributed to the manuscript.

Acknowledgements: Special thanks to Dr. Manar Mudhafar for her histological readings. Also to Dr. Alyaa I. Naser and Dr. Ziad H. Deleme for their support during this research.

Cite as: Salim HA. Comparison of Ostene® and Bone wax on Bone Healing: A Comparative experimental study in rabbits. *J Oral Res* 2018; 7(9):426-431.
[doi:10.17126/joralres.2018.082](https://doi.org/10.17126/joralres.2018.082)

Abstract: Introduction: Ostene® is a new synthetic bone hemostatic wax-like inert and biocompatible material that dissolves within two days after application. Bone wax is a well-known topical hemostatic agent, easy to use, and its application is very simple. Wound healing is a complex biological process; Bone is a dynamic tissue that is continuously resorbed, renewed, and remodeled. Materials and methods: Twenty domestic rabbits were divided into four groups (day 1, day 3, day 7, and day 14). Each rabbit was anaesthetized and three holes were drilled in the mandible: one was filled with Ostene®, another with bone wax, and the other was left unfilled as control. Sites of intervention were assessed by histopathology. Results and Discussion: Ostene® and bone wax showed osteoinductive property in bone healing with no inflammatory reaction. Our study revealed new bone formation within 14 days in Ostene® group. After histopathological analysis and scoring was finished, analysis by SPSS 14 software showed a significant difference between the use of Ostene® and bone wax. Conclusion: Ostene® showed superiority over bone wax in bone healing, and it can be used in the same way as bone wax with no interference with bone healing and osteogenesis. Ostene® has no side effects following application.

Keywords: Bone hemostatic agents; ostene; bone wax; bone healing; alkylene oxide copolymers.

INTRODUCTION.

Bone is a biologically highly dynamic vascularized living tissue, constant undergoing adaptation to the mechanical and metabolic demand of the body by means of bone regeneration and repair, as a result of the balance between the activity of osteoblasts and osteoclasts.¹⁻⁴

Bones are largely made up of an organic matrix (osteoid) and the calcium hydroxyapatite mineral, which gives the bones strength and hardness. It is continuously resorbed, renewed, and remodeled. These processes are carried out by several different types of bone cells that are regulated by a number of transcription factors, cytokines, and growth factors.⁵

Osteoblasts are mature cells that are actively mobile, located on the surface of bones. These cells synthesize, transport, and arrange many proteins of matrix and bone forming cells.^{5,6} Osteoclasts are multinucleated cells which are responsible for bone resorption. They are larger than osteoblasts and osteocytes.^{5,7}

The healing process of bone has three overlapping stages: inflammation, bone production, and bone remodeling. Regeneration can occur by three different mechanisms: osteogenesis, which is formation of new bone from bone forming cells; osteoconduction, the physical property of the graft to serve as a scaffold for new bone growth; and osteoinduction, which is a process whereby one tissue, or product derived from it, causes a second undifferentiated tissue to differentiate into bone. Bone healing processes depend mostly on osteoinduction.⁸⁻¹⁰

Ostene® is a new synthetic bone hemostatic wax like material made of water-soluble alkylene oxide copolymers (AOC). It is composed of a sterile mixture of hydrophilic, biocompatible copolymers derived from ethylene oxide and propylene oxide. It is an inert material and dissolves from the bone within 48 hours after application and it is excreted from the body unchanged through renal clearance safely without metabolism.¹¹⁻¹⁶

Ostene® is applied in a similar fashion as bone wax and to a thickness of 1-2mm; it does not cause infection, nor induce inflammatory reactions, and it does not interfere with coagulation, nor with osseous union.¹⁴⁻¹⁸

AOC have a long history of use in the medical and pharmaceutical field, its approved by the U.S Food and Drug Administration, it dissolves from the site of application faster than other materials, and it is also hypothesized that AOC permits faster bone healing than other resorbable hemostatic agents.^{19,20} Ostene® may be a better alternative to bone wax due to its water solubility.^{13,21}

Bone wax is a well-known topical hemostatic agent, composed of cera alba (beeswax) (88%) and isopropyl palmitate (12%), a palm oil-based emollient, moisturizer, and thickening and anti-static agent.²²⁻²⁵

Bone wax is relatively easy to use, and its application is very simple. It is a non-absorbable hemostatic sealant and it functions as a mechanical tamponade to stop bone bleeding in patients undergoing thoracic, orthopedic, craniofacial and neurosurgery.^{26,27}

This study aims to evaluate and compare the effects of Ostene® and bone wax in the healing process of the mandibular bone of the rabbit.

MATERIALS AND METHODS.

Study design

Twenty domestic rabbits were selected and divided into four groups according to sacrificing day: (day 1, day 3, day 7, and day 14).

Three holes were drilled in each rabbit's mandible, these holes filled with different materials: one filled with Ostene®, the other filled with bone wax, and the last one left unfilled, as a control.

Surgical protocol

All surgery was done under general anesthesia, each animal was injected intramuscularly in the thigh muscle with 40 mg/kg ketamine and 4mg/kg xylazine.^{26,28,29}

Ten minute after anesthesia, shaving and cleansing of the skin was performed, then under aseptic conditions, a 1 cm incision was made under the mandible, and the mandibular bone was exposed.

Three holes were drilled with a 2mm spherical dental burr to assure a standardized defect with equal depth and the drilling was done under irrigation with normal saline, two holes in the right side the nearest one to the midline filled with Ostene® and the second one filled with bone wax, the other hole in the left side was left unfilled, as a control. Suturing was then performed using sterile synthetic absorbable, Vicryl suture size 2-0.

Histopathological study

At the day of sacrificing, each mandible was dissected and fixed in 10% neutral buffered formalin, followed by decalcification of the bone to complete processing for the preparation of slides and staining with hematoxylin eosin. The histopathological scoring used was that of Sultana and Solchagal^{30,31} with small modifications, as the follows:

A. Amount of granulation tissue:

- 1.Profound.
- 2.Moderate.
- 3.Scant.
- 4.Absent.

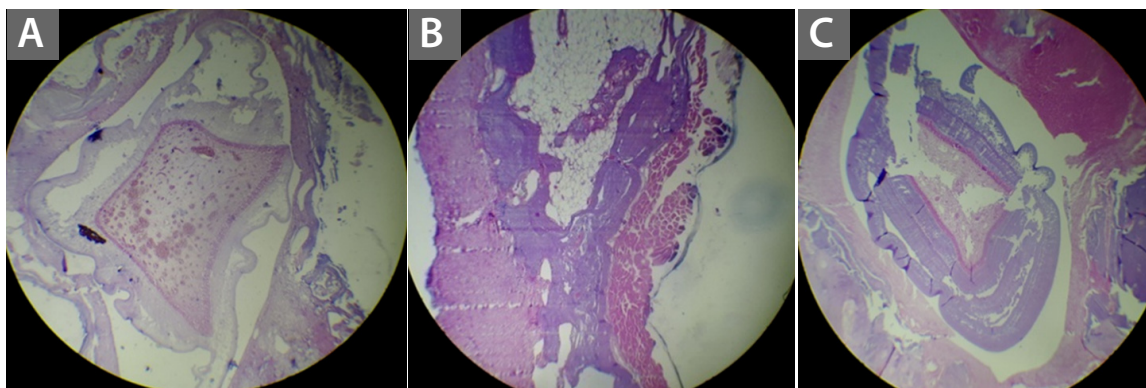
B. Inflammatory infiltrate:

- 1.Plenty.
- 2.Moderate.
- 3.Few.
- 4.Absent.

C. De novo formation of blood vessels:

- 0.Absent.
 1.Present peripherally.
 2.Present centrally.
 3.Present centrally and peripherally.
- D. Presence of osteoblasts:**
 0.Absent.
 1.Present peripherally.
- 2.Present centrally.
 3.Present centrally and peripherally.
- E. Presence of osteoclasts:**
 0.Absent.
 1.Present peripherally.
 2.Present centrally.
 3.Present centrally and peripherally.

Figure 1. Histopathological section of three groups.



A. Ostene®. B. Bone wax. C. Control.

Table 1. Comparison of the inflammatory variable between the three groups using Friedman test.

Periods	Mean Ranks for control	Mean Ranks for bone wax	Mean Ranks for Ostene®	p –value
Day 1	1.20	2.10	2.70	0.042*
Day 3	1.10	2.20	2.70	0.029*
Day 7	1.80	2.40	1.80	0.135
Day 14	2.70	2.30	1.00	0.010*

*: p-value: ≤ 0.05

Table 2. Comparison of the granulation tissue variable comparison variable between the three groups using Friedman test.

Periods	Mean Ranks for Ostene®	Mean Ranks for bone wax	Mean Ranks for control	p –value
Day 1	1.50	2.00	2.50	0.146
Day 3	2.90	1.90	1.20	0.021*
Day 7	2.00	1.40	2.60	0.050*
Day 14	Equal	Equal	Equal	Equal

*: p-value: ≤ 0.05

Table 3. Comparison of the Blood vessels variable comparison variable between the three groups using Friedman test.

Periods	Mean Ranks for Ostene®	Mean Ranks for bone wax	Mean Ranks for control	p –value
Day 1	2.80	2.10	1.10	0.014*
Day 3	2.70	2.10	1.20	0.022*
Day 7	2.70	1.60	1.70	0.128
Day 14	2.20	2.00	1.80	0.779

*: p-value: ≤ 0.05

Table 4 . Comparison of the Osteoblast variable comparison variable between the three groups using Friedman test.

Periods	Mean Ranks for Ostene®	Mean Ranks for bone wax	Mean Ranks for control	p –value
Day 1	2.80	1.60	1.60	0.018*
Day 3	2.90	1.70	1.40	0.015*
Day 7	2.70	2.00	1.30	0.030
Day 14	2.40	2.50	1.10	0.022

*: p-value: ≤ 0.05

Table 5 . Comparison of the Osteoclast variable comparison variable between the three groups using Friedman test

Periods	Mean Ranks for Osten®	Mean Ranks for bone wax	Mean Ranks for control	p –value
Day 1	2.40	1.80	1.80	0.368
Day 3	2.70	1.80	1.50	0.039*
Day 7	2.70	2.20	1.10	0.024*
Day 14	2.30	2.70	1.00	0.016*

*: p-value: ≤ 0.05

RESULTS.

After all animals were sacrificed as scheduled, analysis of the differences between the three experimental groups with Friedman test was performed. (Tables 1, 2, 3, 4 and 5) In the Ostene® group enhance bone healing was apparent at 14 days illustrated by woven bone during this period. Abundance of bone trabeculae can be seen in histopathological section with a great amount of granulation tissue. (Figure 1A, Table 2)

For the control group, normal bone healing occurred as expected during the healing period. Regarding the bone wax group, healing occurred to a lesser degree than in Ostene® group, granulation tissue and bone trabeculae was found in histopathological section but in lesser amounts compared to the Ostene® group. (Table 2)

DISCUSSION.

Ostene® appears to have many advantages over bone wax as it did not cause inflammation in excess while bone wax did. Furthermore Ostene® is removed from the body unchanged while bone wax is not. Our results are in agreement with Gurcan *et al.*,²³ who showed that the advantages of Ostene® over bone wax is that Ostene® is absorbed within two days, in addition to

that it does not have adverse effects on healing and is excreted unchanged by the body. Nooh *et al.*,²⁷ informed a foreign body reaction to bone wax in the form of granulomatous inflammation and fibrous encapsulation with the inhibition of bone healing and osteogenesis. In addition, Vestergaard *et al.*,³² showed that bone wax significantly inhibits bone healing and induces chronic inflammation in pigs whereas Ostene® did not.

About granulation tissue, there is a significant difference in most of the groups but it is more marked in the Ostene® group, which may be due to Ostene® dissolving from the site of application within two days, allowing the early phases of bone healing to occur.

This is in agreement with Wellisz *et al.*,¹¹ who showed that the polymer material dissolved from the site of application within 24 to 48 hours allowing early bone healing to occur.

It is reported in Wellisz *et al.*,¹⁸ that bone wax increased infection rates and impaired the ability of bone to clear bacteria. Also this study revealed that bone wax remain as a foreign body at the site of application, and osteoblasts in bone wax group have been shown to be absent in the presence of a thin layer of bone wax. Our study revealed new bone formation (woven bone)

within 14 days in the Ostene® group, in agreement with Wellisz *et al.*,¹¹ who showed that new bone grew within 10 days in a rat femur defect treated with polymer and untreated controls.

Bone wax is insoluble and therefore not resorbable, and it interferes with bone healing at the site of application, it may aid in the development of infection by decreasing bacterial clearance in the cancellous bone and inhibits osteoblasts from reaching bony defects, leading to impaired bone healing, whereas Ostene® does not cause infection, inflammatory reactions, or interference in the osseous union.^{14,21}

Both Wellisz *et al.*,¹⁸ and Wellisz *et al.*,²⁰ found that, although bone wax was effective in stopping bone healing, it remains at the site of application and has a number of adverse effects, forming a physical barrier

to bone healing. All the defects filled with Ostene® showed newly woven bone rich in cellular activity, with no evidence of fibrotic scar tissue, indicating that good healing occurred with an absence of fibrotic scar tissue. This revealed that Ostene® has an anti-fibrosis effect in agreement with results from other studies.^{19,23}

Regarding the histopathological analysis, abundant, poorly organized bony trabeculae with maturation of granulation tissue into the connective tissue was observed the control group during 2nd week; while at the same period in the Ostene® group more organized granulation tissue with bone trabeculae which increased in number, thickness and organization was visible, in contrast to bone wax group who displayed less bone trabeculae in a disorganized manner, a phenomenon corroborated by other studies.¹²

REFERENCES.

1. Venkataraman N, Bansal S, Bansal P, Narayan S. Dynamics of bone graft healing around implants. *J Int Clin Dent Res Organ.* 2015;7(3):40–7.
2. Beriberi A, Samarani A, Nader N, Noujeim Z, Dagher M, Kanj W, Mearawi R, Saleme Z, Badran B. Physicochemical characteristic of bone substitutes used in oral surgery in comparison to autogenous bone. *BioMed Research International.* 2014;320790:1–9.
3. Neal D. Peterson's principles of oral and maxillofacial surgery. 2nd Ed. Hamilton, London: Decker Inc; 2004.
4. Khan WS, Rayan F, Dhinsa BS, Marsh D. An Osteoconductive, Osteoinductive, and Osteogenic Tissue-Engineered Product for Trauma and Orthopaedic Surgery: How Far Are We? *Stem Cells Inter.* 2012;2012(236231):1–7.
5. Kumar V, Abbas AK, Aster JC. Robbins and Cotran Pathologic Basis of Disease. 8th Ed. Philadelphia: Saunders; 2010.
6. Kalfas IH. Principles of bone healing. *Neurosurg Focus.* 2001;10(4):E1.
7. Nather A., Nather A, Ong HJC, Aziz Z. Bone Grafts and Bone Substitutes. Basic Science and Clinical Applications. 1st Ed. Singapore: World Scientific Pub Co Inc; 2005. Structure of Bone; 3–17.
8. Peres JA, Lamano T. Strategies for stimulation of new bone formation: a critical review. *Braz Dent J.* 2011;22(6):443–8.
9. Li J, Wang HL. Common implant-related advanced bone grafting complications: classification, etiology, and management. *Implant Dent.* 2008;17(4):389–401.
10. Albrektsson T, Johansson C. Osteoinduction, osteoconduction and osseointegration. *Eur Spine J.* 2001;10(Suppl 2):S96–101.
11. Wellisz T, An YH, Wen X, Kang Q, Hill CM, Armstrong JK. Infection rates and healing using bone wax and a soluble polymer material. *Clin Orthop Relat Res.* 2008;466(2):481–6.
12. Sawan A, Elhawary Y, Amer MZ, Rahman MA. Controversial Role of Two Different Local Haemostatic Agents on Bone Healing. *J Am Sci.* 2010;6(12):155–63.
13. Park J, Koh JW. Era of Bloodless Surgery: Spotlights on Hemostatic Materials and Techniques. *Hanyang Med Rev.* 2018;38(1):3–15.
14. Kumar S. Local hemostatic agents in the management of bleeding in oral surgery. *Asian J Pharm Clin Res.* 2016;9(3):35–41.
15. Vestergaard RF, Brüel A, Thomsen JS, Hauge EM, Søballe K, Hasenkam JM. The influence of hemostatic agents on bone healing after sternotomy in a porcine model. *Ann Thorac Surg.* 2015;99(3):1005–11.
16. Vestergaard RF, Nielsen PH, Terp KA, Søballe K, Andersen G, Hasenkam JM. Effect of hemostatic material on sternal healing after cardiac surgery. *Ann Thorac Surg.* 2014;97(1):153–60.
17. Magyar CE, Aghaloo TL, Atti E, Tetradis S. Ostene, a new alkylene oxide copolymer bone hemostatic material, does not inhibit bone healing. *Neurosurgery.* 2008;63(4 Suppl 2):373–8.
18. Armstrong JK, Han B, Kuwahara K, Yang Z, Magyar CE, Dry SM, Atti E, Tetradis S, Fisher TC. The effect of three hemostatic agents on early bone healing in an animal model. *BMC Surg.* 2010;10:37.
19. Armstrong JK, Han B, Kuwahara K, Yang Z, Magyar CE, Dry SM, Atti E, Tetradis S, Fisher TC. The effect of three hemostatic agents on early bone healing in an animal model. *BMC Surg.* 2010;10:37.
20. Wellisz T, An YH, Wen X, Kang Q, Hill CM, Armstrong JK. Infection rates and healing using bone wax and a soluble polymer material. *Clin Orthop Relat Res.* 2008;466(2):481–6.
21. Morrison J. Topical Hemostatic Agents: A Review of the Literature. *NOFA J.* 2016;3(3)
22. Schonauer C, Tessitore E, Barbagallo G, Albanese V, Moraci A. The use of local agents: bone wax, gelatin, collagen, oxidized cellulose. *Eur Spine J.* 2004;13(Suppl 1):S89–96.
23. Gurcan O, Gurcay AG, Kazanci A, Onder E, Senturk S, Bavbek M. Is the use of hemostatic matrix (FloSeal) and alkylene oxide copolymer (Ostene) safe in spinal laminectomies? Peridural fibrosis assessment. *Acta Orthop Traumatol Turc.* 2017;51(2):165–8.
24. Raposo-Amaral CE, de Almeida ABA, Paschoal G, Bueno DF, Vulcano LC, Passos-Bueno MR, Alonso N. Histological and radiological changes in cranial bone in the presence of bone wax. *Acta Cir Bras.* 2011;26(4):274–8.
25. Sudmann B, Anfinson OG, Bang G, Koppang R, Stølen

- SØ, Koppang HS, Sudmann E. Assessment in rats of a new bioerodible bone-wax-like polymer. *J Acta Orthopaedica Scandinavica*. 1993;64(3):336–9.
26. von Arx T, Jensen SS, Hänni S, Schenk RK. Haemostatic agents used in periradicular surgery: an experimental study of their efficacy and tissue reactions. *Int Endod J*. 2006;39(10):800–8.
27. Nooh N, Abdullah WA, Grawish Mel-A, Ramalingam S, Javed F, Al-Hezaimi K. The effects of surgicel and bone wax hemostatic agents on bone healing: An experimental study. *Indian J Orthop*. 2014;48(3):319–25.
28. Paknejad M, Rokn AR, Eslami B, Afzalifar R, Safiri A. Evaluation of Three Bone Substitute Materials in the Treatment of Experimentally Induced Defects in Rabbit Calvaria. *J Dentistry, Tehran University Med Scie*. 2007;4(4):171–6.
29. Kilic N. A Comparison between Medetomidine-Ketamine and Xylazine-Ketamine Anaesthesia in Rabbits. *Turk J Vet Anim Sci*. 2004;28:921–6.
30. Sultana J, Molla M, Kamal M, Shahidullah M, Bashar M. Histological differences in wound healing in Maxillofacial region in patients with or without risk factors. *Bangladesh J Pathology*. 2009;24(1):3–8.
31. Solchaga LA, Yoo JU, Lundberg M, Dennis JE, Huibregtse BA, Goldberg VM, Caplan AI. Hyaluronan-based polymers in the treatment of osteochondral defects. *J Orthop Res*. 2000;18(5):773–80.
32. Vestergaard RF, Jensen H, Vind-Kezunovic S, Jakobsen T, Søballe K, Hasenkam JM. Bone healing after median sternotomy: a comparison of two hemostatic devices. *J Cardiothorac Surg*. 2010;5:117.